

August 2015

The Effects of 830nm Light on Inflammation in Retinitis Pigmentosa

Krystal Marie Bach

University of Wisconsin-Milwaukee

Follow this and additional works at: <https://dc.uwm.edu/etd>

 Part of the [Allergy and Immunology Commons](#), [Neuroscience and Neurobiology Commons](#), and the [Physiology Commons](#)

Recommended Citation

Bach, Krystal Marie, "The Effects of 830nm Light on Inflammation in Retinitis Pigmentosa" (2015). *Theses and Dissertations*. 944.
<https://dc.uwm.edu/etd/944>

This Thesis is brought to you for free and open access by UWM Digital Commons. It has been accepted for inclusion in Theses and Dissertations by an authorized administrator of UWM Digital Commons. For more information, please contact open-access@uwm.edu.

THE EFFECTS OF 830NM LIGHT ON INFLAMMATION IN RETINITIS PIGMENTOSA

by

Krystal M. Bach

A Thesis Submitted in

Partial Fulfillment of the

Requirements for the Degree of

Master of Science

in Biomedical Sciences

at

The University of Wisconsin-Milwaukee

August 2015

ABSTRACT

THE EFFECT OF 830NM LIGHT ON INFLAMMATION IN RETINITIS PIGMENTOSA

by

Krystal M. Bach

The University of Wisconsin-Milwaukee, 2015
Under the Supervision of Dr. Janis T. Eells

Purpose: Retinitis Pigmentosa (RP) is an inherited retinal degenerative disease and the most common cause of blindness in developed countries, affecting approximately 1 in 4,000 people. RP is characterized by photoreceptor cell death and recent studies suggest that chronic inflammation may play a key role in the pathogenesis of RP. Currently, there are no known treatments or preventive measures to delay or halt the loss of photoreceptor cells. Photobiomodulation (PBM) by light in the far-red or near-infrared (NIR) range of the light spectrum has been documented to help promote cell survival and reduce inflammation in several disease states. Recent studies in the P23H rat model of RP have shown that 830nm PBM attenuated photoreceptor cell loss and protected retinal function. The current studies test the hypothesis that 830nm PBM produces an anti-inflammatory environment in the retina to protect against photoreceptor cell loss.

Methods: Studies were conducted in compliance with the ARVO Statement for the Use of Animals in Ophthalmic and Visual Research. P23H rats were irradiated with 830nm light (180 s; 25 mW/cm²; 4.5 J/cm²) using a light-emitting diode array once per day from postnatal day (p)17 to 27. Sham treated controls

were restrained for 180 seconds, but not exposed to the 830nm light. Retinas were harvested at p30. Retinal concentrations of ten inflammatory mediators were determined using a multiplex bead-based immunosorbent assay.

Results: Our findings indicate that retinal concentrations of four of the ten inflammatory mediators, CINC-3, IL-10, VEGF, and TIMP-1 differed between the dystrophic P23H rats and the non-dystrophic SD rats. Statistically significant differences were only observed in TIMP-1, with concentrations in the P23H retinas that were twice that measured in the SD retinas. 830nm PBM produced no changes in retinal concentrations of the 10 inflammatory mediators measured compared to the sham treatment.

Conclusion: Our data indicated that the inflammatory environment of the dystrophic P23H rat and the non-dystrophic SD rat differ. The data also shows that 830nm PBM had no measurable effect on these inflammatory mediators at p30. Further studies with greater numbers of animals are needed to investigate the time course of inflammation in this rodent model of RP and to define potential effects of PBM.

This work is dedicated to my parents who have supported and encouraged me,
not only during these last three years, but through-out my academic career.

Without them I would not have been able to accomplish all that I have.

TABLE OF CONTENTS

LIST OF FIGURES.....	VIII
LIST OF ABBREVIATIONS	X
ACKNOWLEDGEMENTS	XIII
CHAPTER 1: INTRODUCTION.....	1
I. Background	1
Retinitis Pigmentosa.....	1
Etiology.....	1
Clinical Manifestations	4
Current Treatments.....	8
Ocular Immunity.....	14
Immune Regulation.....	14
Inflammation	18
Photobiomodulation	22
II. Hypothesis and Specific Aims	26
CHAPTER 2: MATERIALS AND METHODS.....	28
I. Animal Model.....	28
II. Near Infrared Light Treatment.....	29
III. Tissue Collection.....	29
IV. Evaluation of Protein Concentration.....	30
V. Assessment of Cytokine and Chemokine Concentrations	31
VI. Statistics.....	31

CHAPTER 3: RESULTS	32
I. Rationale	32
II. Compare the concentrations of pro-inflammatory mediators in the retinas of non-dystrophic SD rats with P23H rats and determine the effect of 830nm light on pro-inflammatory mediators in the retina of SD and P23H rats.....	37
Concentrations of Pro-Inflammatory Mediators in the P23H Rat Retina	37
Effects of 830nm Light on Retinal Concentrations of Pro-Inflammatory Mediators	39
III. Compare the concentrations of anti-inflammatory mediators in the retinas of non-dystrophic SD rats with P23H rats and determine the effect of 830nm light on anti-inflammatory mediators in the retina of SD and P23H rats.....	43
Concentrations of Anti-Inflammatory Mediators in the P23H Rat Retina.....	43
Effects of 830nm Light on Retinal Concentrations of Anti-Inflammatory Mediators	45
CHAPTER 4: DISCUSSION.....	48
I. Compare the concentrations of pro-inflammatory mediators in the retinas of non-dystrophic SD rats with P23H rats and determine the effect of 830nm light on pro-inflammatory mediators in the retina of SD and P23H rats.....	49
II. Compare the concentrations of anti-inflammatory mediators in the retinas of non-dystrophic SD rats with P23H rats and determine the effect of 830nm light on anti-inflammatory mediators in the retina of SD and P23H rats.....	52
III. Discussion	54
CHAPTER 5: CONCLUSIONS AND FUTURE DIRECTIONS	61

REFERENCES	65
------------------	----

LIST OF FIGURES

Figure 1. Concentration of IL-6 found in retinal samples of sham treated Sprague-Dawley rats (n=4), 830m light treated Sprague-Dawley rats (n=5), sham treated P23H rats (n=5), and 830nm P23H rats (n=6). Retinal samples were obtained at p30. Error bars indicate SEM. No statistically significant differences (P<0.05).....	38
Figure 2. Concentration of TNF- α found in retinal samples of sham treated Sprague-Dawley rats (n=4), 830m light treated Sprague-Dawley rats (n=5), sham treated P23H rats (n=5), and 830nm P23H rats (n=6). Retinal samples were obtained at p30. Error bars indicate SEM. No statistically significant differences (P<0.05).....	39
Figure 3. Concentration of IFN- γ found in retinal samples of sham treated Sprague-Dawley rats (n=4), 830m light treated Sprague-Dawley rats (n=5), sham treated P23H rats (n=5), and 830nm P23H rats (n=6). Retinal samples were obtained at p30. Error bars indicate SEM. No statistically significant differences (P<0.05).....	40
Figure 4. Concentration of VEGF found in retinal samples of sham treated Sprague-Dawley rats (n=4), 830m light treated Sprague-Dawley rats (n=5), sham treated P23H rats (n=5), and 830nm P23H rats (n=6). Retinal samples were obtained at p30. Error bars indicate SEM. No statistically significant differences (P<0.05).....	41
Figure 5. Concentration of CINC-3 found in retinal samples of sham treated Sprague-Dawley rats (n=4), 830m light treated Sprague-Dawley rats (n=5), sham treated P23H rats (n=5), and 830nm P23H rats (n=6). Retinal samples were obtained at p30. Error bars indicate SEM. No statistically significant differences (P<0.05).....	42
Figure 6. Concentration of IL-1 α found in retinal samples of sham treated Sprague-Dawley rats (n=4), 830m light treated Sprague-Dawley rats (n=5), sham treated P23H rats (n=5), and 830nm P23H rats (n=6). Retinal samples were obtained at p30. Error bars indicate SEM. No statistically significant differences (P<0.05).....	42

Figure 7. Concentration of IL-13 found in retinal samples of sham treated Sprague-Dawley rats (n=4), 830m light treated Sprague-Dawley rats (n=5), sham treated P23H rats (n=5), and 830nm P23H rats (n=6). Retinal samples were obtained at p30. Error bars indicate SEM. No statistically significant differences ($P<0.05$)..... 43

Figure 8. Concentration of IL-4 found in retinal samples of sham treated Sprague-Dawley rats (n=4), 830m light treated Sprague-Dawley rats (n=5), sham treated P23H rats (n=5), and 830nm P23H rats (n=6). Retinal samples were obtained at p30. Error bars indicate SEM. No statistically significant differences ($P<0.05$)..... 44

Figure 9. Concentration of IL-10 found in retinal samples of sham treated Sprague-Dawley rats (n=4), 830m light treated Sprague-Dawley rats (n=5), sham treated P23H rats (n=5), and 830nm P23H rats (n=6). Retinal samples were obtained at p30. * denotes a statistically significant difference ($P<0.05$). Error bars indicate SEM. 45

Figure 10. Concentration of TIMP-1 found in retinal samples of sham treated Sprague-Dawley rats (n=4), 830m light treated Sprague-Dawley rats (n=5), sham treated P23H rats (n=5), and 830nm P23H rats (n=6). Retinal samples were obtained at p30. * denotes a statistically significant difference ($P<0.05$). Error bars indicate SEM. 46

LIST OF ABBREVIATIONS

ACAID: anterior chamber associated immune deviation (ACAID).

AMD: age-related macular degeneration

ANOVA: analysis of variance

APC: antigen presenting cell

ATF6: activating transcription factor 6

ATP: adenosine triphosphate

BiP: binding immunoglobulin protein

BRB: blood retinal barrier

CcO: Cytochrome c oxidase

CINC-3: cytokine-induced neutrophil chemoattractant-3

DHA: docosahexaenoic acid

EAE: experimental autoimmune encephalomyelitis

ELISA: enzyme-linked immunosorbent assay

ER: endoplasmic reticulum

ERG: Electroretinogram

FA: fluocinolone acetonide

FR: far-red

GFAP: glial fibrillary acidic protein

GRO- α : growth regulated oncogene- α ,

IFN: interferon

IFN- γ IP-10: interferon-gamma inducible protein-10

IL: interleukin

IRE-1: inositol-requiring protein-1

LCA: Leber congenital amaurosis

MAC-IP: membrane attack complex inhibitory protein

MCP: monocyte chemoattractant protein

MHC: major histocompatibility complex

MIP: monocyte chemoattractant protein

MMP: matrix metalloproteinase

NIR: near infrared

NK cells: Natural Killer cells

NO: nitric oxide

ONL: outer nuclear layer

PBM: Photobiomodulation

PCR: polymerase chain reaction

PDE6: phosphodiesterase 6

PERK: protein kinase RNA-like ER kinase

rAAV: recombinant adeno-associated virus

RANTES: regulated on activation normal T cell expressed and secreted

RBC: red blood cell

RCS: Royal College of Surgeon

RNAi: RNA interference

ROS: reactive oxygen species

RP: Retinitis Pigmentosa

RPE: retinal pigment epithelium

SD: Sprague-Dawley

TARC: thymus and activation-regulated chemokine

TGF- β : transforming growth factor β

TIMP-1: tissue inhibitor of metalloproteinase-1

TLR: toll-like receptors

TNF- α : tumor necrosis factor- α

UPR: unfolded protein response

VEGF: vascular endothelial growth factor

ACKNOWLEDGEMENTS

I would like to extend my sincerest thanks to my professors, Dr. Janis Eells and Dr. Dean Nardelli, for their constant support and guidance not only throughout this project, but in all aspects of my academic work at UW-Milwaukee. Their insights and advice has been invaluable as I explored the many opportunities available to me in the field of research.

I would also like to thank Dr. Jeri-Anne Lyons for her input and support as a committee member, and Dr. Douglas Steeber for being on my proposal committee.

In addition, I want to acknowledge and thank all those who have assisted with the completion of this project. Specifically, Dr. Elizabeth Liedhegner, whose assistance made the bioplex assay and analysis possible, and Dr. Jenifer Coburn, at the Medical College of Wisconsin, who allowed us to use her Magnetic Luminex MAGPIX Analyzer to perform our bioplex assays. Also, my fellow lab members Naoki Shimoyama, for his initial work starting this research project, and Emily Hansen for all of her help in the lab.

Lastly, this work would not have been able to be performed without the financial support of the College of Health Sciences and Biomedical Sciences Department's scholarships and fellowships, or the funding of the CHS Student Research Grant.

CHAPTER 1: INTRODUCTION

I. Background

Retinitis Pigmentosa

Etiology

Retinitis Pigmentosa (RP) is a group of inherited retinal degenerative diseases that cause the progressive loss of vision due to the death of photoreceptor cells. RP is the most common cause of blindness in developed countries and affects approximately 1 in 4,000 people, worldwide (1-5). RP is an extremely heterogenic disease with multiple modes of inheritance. It is estimated that 30-40% of all RP cases are caused by autosomal dominant mutations, 50-60% are caused by autosomal recessive mutations, 5-15% are X-linked, and a small portion exhibit complex polygenic inheritance and non-Mendelian inheritance (1, 5-7). In addition, RP has been associated with over 30 different syndromes. These syndromic conditions account for 20-30% of all RP cases (1, 8, 9). The most common RP syndromes are Usher syndrome (10-20% of RP cases) and Bardet-Biedl syndrome (5-6% of RP cases) (1, 8, 10).

Over 45 gene loci have been shown to be involved in RP, with genetic mutations affecting a wide variety of metabolic pathways. Mutations have been characterized in the phototransduction cascade, from protein trafficking to metabolic functions, and in cellular structures both inside and outside the ocular tissues (1, 8, 9). Although most mutations only account for a very small

percentage of RP cases, there are few exceptions. The most commonly affected genes are *RPGR*, *USH2A*, and *RHO*. Together, mutations in these three genes represent 30% of all RP cases (1, 9). Mutations in the *RHO* gene, which encodes for the G-protein coupled photon receptor rhodopsin, are the most common. These mutations are present in 25% of autosomal dominant cases of RP, and 8-10% of all cases of RP (1, 11-14).

RHO is a highly conserved 7,000 base pair gene among vertebrates (11, 15). It codes for a 348 amino acid light sensitive protein, also known as an opsin. Opsin is a seven segment transmembrane protein located in the discs of the outer segments of photoreceptor cells. The seven transmembrane segments form a pocket with a lysine residue in the middle. This residue binds the chromophore 11-*cis*-retinal, which is derived from vitamin A (11). It is this chromophore and opsin together that form the visual pigment rhodopsin, which absorbs light in the eye initiating the visual cycle (15). Therefore, it is no surprise that defects in *RHO* have the potential to severely impair vision. Over 40 mutations and deletions known to cause RP have been found in *RHO* (11, 16). These mutations impair normal protein folding and transportation, rhodopsin's incorporation into the photoreceptor's outer segments, the binding of 11-*cis*-retinal, and the G-protein coupling and activation of rhodopsin (11, 15).

Of the mutations affecting the rhodopsin molecule, the P23H mutation is the most commonly reported, causing 12% of all autosomal dominant RP cases (12, 17). The P23H mutation is caused by a single base-pair substitution, changing a cytosine to an adenine in the 23rd codon. Normally, this codon

produces the amino acid proline, but the mutation results in a histidine being placed at that location instead (17). The exact function of the proline at codon 23 is unknown; however, this particular codon is very highly conserved, as it is present in the same location in other opsins and rhodopsin homologs of vertebrates and invertebrates alike (17). It has been demonstrated that the P23H mutant rhodopsin is misfolded due to the substitution. This misfolding results in the inability of the 11-*cis*-retinal chromophore to properly incorporate into the rhodopsin molecule. The mutant rhodopsin is also less photosensitive, and is rapidly degraded due to its instability in the cells (12). Approximately 10% of the mutant rhodopsin produced is successfully transported to the outer segments of the photoreceptors (18). This greatly impacts the rod photoreceptor cells' ability to function, as 90% of all the proteins found in the outer segment are rhodopsin (15). The misfolded proteins that do successfully integrate into the outer segment membranes cause the photoreceptor cell to be structurally disorganized, and it has been proposed that this disorganization is a potential cause of the photoreceptor cell degeneration (18). In addition, the misfolded protein tends to aggregate in the endoplasmic reticulum (ER), where it is produced (12, 19, 20). The accumulation of misfolded proteins generates stress in the ER and activates the unfolded protein response (UPR). The UPR attempts to either repair or eliminate misfolded proteins by upregulating the production of the ER stress transducers inositol-requiring protein-1 (IRE-1), protein kinase RNA-like ER kinase (PERK), and activating transcription factor 6 (ATF6). The molecular chaperone binding immunoglobulin protein (BiP), which is found in the lumen of

the ER, senses the misfolded rhodopsin proteins and activates the stress transducers. Once activated, IRE-1, PERK, and ATF6 promote the degradation of the misfolded proteins by either ER-associated protein degradation (ERAD) or autophagy (21). However, as the mutant proteins are constantly being reproduced, it is suggested that the UPR is overwhelmed as the cell cannot adapt to the constant stress or attenuate the UPR due to the excessive degradation occurring. This results in an increased production of reactive oxygen species (ROS), which triggers a cascade of pro-apoptotic signals, leading to the death of photoreceptor cells (19, 21, 22).

Clinical Manifestations

Although RP is actually an umbrella term for many similar yet heterogeneous retinopathies, RP is generally characterized by the degeneration rod photoreceptors followed by a secondary deterioration of the cone photoreceptors (1, 8). This step-wise degeneration of the photoreceptors makes the typical progression of the disease definable in three stages known as early, mid, and end stage RP (8).

The early stage commonly occurs during the early or adolescent years (1, 8). At this point, the rods are just beginning to degrade and the only symptom is a mild night blindness or difficulties adjusting to dark conditions. This is due to a ring scotoma, or blind spot, that begins to form in the mid-periphery of the visual field (1, 8, 11, 23). Symptoms at this stage can be easily missed as artificial

lighting may help conceal the defect, and the patient may not notice any difficulties during their day-to-day activities. Even if the patient is examined, tests are usually performed in light conditions that do not reflect the dark conditions needed to diagnose the loss of vision (1, 8). An examination of the retina is also of limited use at this stage, as the fundus has a relatively normal appearance with potentially only a slight attenuation of the retinal arterioles (8, 11, 23).

During the mid-stage of the disease, the ring scotoma has progressed into the far-peripheral field of vision and is noticeable in day light conditions, as well as, at night (1, 17, 23, 24). The night blindness is pronounced and affects routine activities (8). The patient may also begin to experience photophobia in diffuse light conditions (8). In addition, at this stage the cone photoreceptors are beginning to degenerate, and color vision may be affected. In particular, there is a decreased detection of pale colors such as blue and yellow (1, 8, 11). The retina begins to have an abnormal appearance. Bone-spicules, which are areas of exposed retinal epithelial (RPE) cells due to the death of the covering photoreceptor cells (25), are found in the periphery of the fundus. There is also an obvious narrowing of the retinal arterioles and a slight paling of the optic disc (8, 11, 23). At this stage of the disease, the development of cataracts is common, occurring in nearly 50% of RP patients (24, 26). With the constriction of the patient's remaining vision into a central field, the development of a cataract can effectively blind the patient if not removed. Throughout the mid-stage the progression of the disease should be carefully monitored, as on average patients

lose 4.6% of their remaining vision per year (23). Once a patient's visual field reaches 10 degrees or less, they are considered legally blind (24).

The end stage occurs when the patient's vision has decayed into a small central field known as tunnel vision (1, 8, 11, 23, 24). The restriction of the patient's vision severely impairs their ability to function. Often, by the age of 40 patients are legally blind, and can lose their remaining central vision by the age of 60 (1, 11). Although only photoreceptor cells degenerate during the early and mid-stages of RP, during the end stage, all retinal cells begin to degenerate (1), resulting in the atrophy of the retina. Furthermore, bone-spicules are found throughout both the macular and peripheral areas of the fundus, the optic disc has waxy appearance, and the retinal vessels are extremely attenuated (8, 11, 17).

RP can be clearly diagnosed and assessed during the latter half of the disease's progression by examining the symptoms; however, attempting to assess RP during its early stages by identifying symptoms can be misleading. As mentioned before, patients often do not notice symptoms during the early stage and it is not until cone degeneration is already involved that patients may report symptoms. It has been observed that while 180 degrees is the normal field of vision, patients with only 130 degrees will not even notice the reduction in vision while performing daily tasks (27). A patient can lose up to 90% of their cones in the fovea before a reduction in vision is even perceived (28). Therefore, clinical assessments of RP need to measure the patient's visual function directly to accurately diagnose early cases of RP.

Electroretinograms (ERGs) are one of the best methods for assessing the development of RP. This non-invasive procedure stimulates the photoreceptors with flashes of light. The electrical response is recorded using an electrode either placed on a contact lens or the eyelid. The response of the rod and cone photoreceptors can be measured together or separately depending on the stimuli used. A rod dominant response can be achieved by dark-adapting the patient's eyes for 20 minutes, then exposing them to a single flash of dim blue light. A flickering 30Hz white light can be used in light-adapted condition to measure the response of only the cones, as stimulus greater than 20Hz are too fast for the rods to follow. To measure the overall response of both photoreceptors, a single bright white flash of light can be used. This produces an "a-wave," which represents the initial hyperpolarization of the photoreceptors, and a "b-wave," which is the subsequent depolarization of the bipolar cells. The amplitudes of each wave form and the time between peaks can be used to determine the functionality of the photoreceptor cells (29, 30). Patients with RP have decreased ERG a-wave and b-wave amplitudes and delayed response times, with the severity depending on the inheritance pattern of the disease and the stage of progression (29, 30). ERGs can be used as effective tools to help diagnose RP, as abnormal responses can be detected years to decades before any symptoms even begin to develop (31).

Current Treatments

There is a large variability between patients with RP due to the genetic heterogeneity and individual environmental factors. This has made the development of effective treatments difficult. Currently, the only treatable forms of RP are those caused by the three metabolic syndromic disorders (32). Bassen-Kornzweig disease, also known as abetalipoproteinemia, is an autosomal recessive disorder that results in the malabsorption of fats and the fat-soluble vitamins A, D, E, and K. Among its other symptoms, the vitamin A deficiency causes retinal degeneration (33, 34). The loss of retinal function in these cases of RP can be reversed with high doses of vitamin A and E supplements if treated before permanent retinal damage occurs (33, 34). The second treatable syndromic RP condition is Refsum's disease, also known as phytanic acid oxidase deficiency. Refsum's disease is a lipid metabolism disorder resulting from a deficiency of phytanic acid hydroxylase. This deficiency causes an accumulation of the fatty acid phytanic acid in serum and tissues, including RPE cells, leading to their degeneration. By maintaining a low phytol and low phytanic acid diet, the development of RP can be avoided (35, 36). The last treatable syndromic RP condition is familial isolated vitamin E deficiency, or α -tocopherol transport protein deficiency, which is caused by mutation in the α -tocopherol transfer protein gene *ttpA* (37). This *ttpA* mutation prevents the proper absorption of vitamin E, resulting in neurodegeneration. High doses of vitamin E supplements are sufficient to counter the deficiency and prevent RP (37).

With the exception of these three syndromic conditions, there has been limited success in developing effective therapies for RP. Gene therapies attempt to correct the defective biochemical pathways, but the method used depends on the specific mutation and inheritance type. Autosomal Recessive mutations are often caused by a mutation which results in the loss of a function, and gene transfer therapies designed for these mutation aim to restore the wild type function. For example, *RPE*^{-/-} dogs are a model of Leber congenital amaurosis (LCA), an inherited retinal degenerative disease similar to RP that occurs within the first few months or years of life. Animals affected with this disease lack an isomerase needed in the retinoid cycling process to change all-*trans*-retinal back into 11-*cis*-retinal. This deficiency results in the accumulation of all-*trans*-retinal and the degeneration of RPE and photoreceptor cells (38, 39). In a study performed by Acland *et al.*, three four-month old *RPE*^{-/-} dogs were injected in the subretinal space with a recombinant adeno-associated virus (rAAV) vector carrying the wild type *RPE65*. The results of ERGs, pupillary response times, and behavioral tests all showed significantly improved visual function 95 days after the injection (38). The experiment was repeated with a larger sample size of 17 dogs and demonstrated that the visual improvement was maintained for at least three years and retinal degeneration was reduced (39). These two studies were used as a proof of concept to initiate clinical trials of the gene therapy; however, when the patients who had received the rAAV-*RPE65* therapy were examined, it was found that although visual function was improved for up to three years, the degeneration of photoreceptors was unabated (40). To further examine the

discrepancies between the canine models and clinical trials, Cideciyan *et al.* compared the natural progression of the disease in humans and various animal models. The *RPE65*^{-/-} dogs had a slower rate of disease progression, with a dysfunctional only phase for 5-8 years before degeneration started, while humans did not have this period and dysfunction and degeneration happened simultaneously. When the dogs were treated at an older age when the dysfunction and degeneration state matched the human disease state at the time of treatment, the gene therapy was unable to slow the rate of degeneration (40).

A different type of gene therapy is needed for cases of RP caused by autosomal dominant mutation, which normally results in the gain of an abnormal function or product. Gene silencing therapies attempt to inhibit or remove the abnormal gene product. RNA interference (RNAi) is one method currently being tested. A study performed by Li Jang *et al.* used a mouse model of autosomal dominant RP to study the long term effects of this technique. Subretinal injections of a rAAV vector carrying the RNAi cassette delayed the photoreceptor degeneration and increased visual function for up to 11 months in the mice (41). While these results are promising, clinical trials of RNAi gene silencing are still in progress and it is unknown if they will face the same problems as the gene transfer treatments. Even if the obstacles of treatment timing with gene therapy are overcome, a unique therapy is required for each mutation, and with only 60% of the causal mutations identified for RP (1), there is still a great deal of research to be done before gene therapy can be an effective treatment option for patients.

Several dietary supplements are used as therapies to slow the rate of retinal degeneration, despite limited clinical evidence. A randomized clinical trial involving 61 RP patients with various inheritance patterns demonstrated that 15,000 IU/day of retinyl palmitate as a vitamin A supplement caused a modest, but significantly lower rate of decline in cone ERG amplitude over the course of four to six years. However, the rate of visual field and acuity loss did not differ from the controls (42). Because of this study, vitamin A supplements are recommended to patients with RP, even though the efficacy of the treatment is still questioned. In addition, there are potential negative side effects to the high doses of vitamin A that patients need to be aware of, such as liver toxicity, osteoporosis in postmenopausal women, and birth defects with pregnant women (43-45). Docosahexaenoic acid (DHA) is another dietary supplement that has been used. DHA is an omega-3 fatty acid found in cell membranes, with particularly high concentrations in photoreceptor cells (46-48). Several studies have examined its effect on the visual function of RP patients, both alone and with other dietary supplements. The first study observed 44 males with X-linked RP who were given either 400mg of DHA per day or a placebo for four years. The patient's ERGs, visual fields, acuity, dark adaptation, and fundus appearance was assessed annually along with the concentration of DHA found in the patient's red blood cells (RBC). No significant differences were observed between the DHA group and the placebo despite significantly elevated levels of RBC DHA concentrations (46). A second study examining the effects of DHA increased the dose and combined it with vitamin A supplements in 208 patients

with various forms of RP. The patients were given either 1,200 mg of DHA with 15,000 IU of retinyl palmitate per day, a control plus 15,000 IU/day of retinyl palmitate, or a control plus a placebo for four years. Again, no significant differences were observed in the annual ERGs or visual field and acuity of the patients (47). However, after further examination of the study's subjects, it was noticed that the patients who were not taking any vitamin A supplements prior to the start of the study had slower rates of vision loss for the first two years when given DHA and retinyl palmitate. It was also noted that while the results were not significant, the patients who had the highest concentration of DHA in their RBCs, had the slowest rates of visual decline. Interestingly, in the control groups that were given only retinyl palmitate or a placebo, it was found that those who consumed 1.4mg/day or more of omega-3 fatty acids in their diet had 40-50% slower rates of visual field loss compared to those who did not (48).

Light protection is another approach to attenuate the rate of retinal degeneration. Animal models provide evidence that bright light exposure increases the degeneration rate of photoreceptors in RP (49), and that either light constraint or constant darkness can slow the rate of degeneration (50). However, case studies examining the effect of light constraint in human eyes has not shown any protective benefits. In two different case studies, a RP patient had one eye normally exposed to light and the other either experimentally covered for six hours a day or closed due to a childhood physical trauma (51, 52). In both cases, when the retinas of the exposed and protected eyes were compared, no differences were observed in the state of disease. However, these cases do not

take into account any potential systemic effects of the light exposure; therefore, more studies are needed to determine the full effect of light protection. Still, it is recommended to patients that they wear amber colored sunglasses with side protection to block ultraviolet and visible light up to 572nm to help reduce photophobia (8).

For the RP patients who have already lost their vision, there are few treatment options that attempt to restore the retinal tissue and visual function. Retinal transplants attempt to insert layers of various retinal and RPE cells into the subretinal space of a degenerated adult retina. However, while these transplanted donor cells seem to survive in the host, the new cells often do not function properly. The transplanted cells show no evidence of developing functional synaptic pathways with the host's neurons, and the transplanted cells tend to form rosettes instead of organizing into the appropriate retinal layer. Similar difficulties have been observed with transplanted stem cells, as these cells do not seem to be able to integrate into the host's retina and develop into photoreceptor cells (53). Maclaren *et al.* proposed that these issues may be overcome if committed photoreceptor precursor cells were used instead of stem cells or developed cells. In 2006, Maclaren *et al.* demonstrated with a murine model that by harvesting the donor cells from a developing retina during the peak of rod photoreceptor genesis and injecting them into the subretinal space of an adult retina, the transplanted cells were able to integrate properly into the outer nuclear layer of the retina and develop into mature rod photoreceptors with the correct morphology. Furthermore, when transplanted in this manner into three

different murine models of inherited retinal degeneration, these cells were able to integrate into the degenerated retina, form functional synaptic connections, and improve visual function (53). Retinal prosthetics are another treatment that show promise for patients completely blinded by RP. Several studies testing 16-electrode epiretinal implants in the eyes of patients blinded by RP have shown the device is able to allow the patient to sense light, directions of motion, and differentiate an object's spatial orientation (54, 55). It is hoped that by increasing the electrode numbers and density in the implants, the patients will experience greater visual function with better resolution.

There is still much research to be done before a truly effective treatment option is available for patients with RP. Although much is known about the majority of the genetic mutations and the phenotypic manifestations, relatively little is known about the mechanisms of the disease. The heterogenetic nature of RP makes it unlikely that one treatment will be effective for all RP patients; increasing our understanding of the biochemical and cellular changes that drive the progression of RP is key to the development of any effective treatments.

Ocular Immunity

Immune Regulation

The eye is considered to be an immune privileged organ, meaning it has a unique tolerance to the presence of antigens, severely limiting any potential inflammatory response. The specialized cells found in the ocular tissue are highly

sensitive to damage, and like most neurons, are postmitotic and have limited regenerative capabilities (56). Therefore, the collateral damage caused by a robust inflammatory response may do more harm than good. The eye limits its immune reactivity using several different mechanisms. One mechanism it uses is known as anterior chamber associated immune deviation (ACAID). ACAID is a specialized method for developing systemic tolerance to retinal antigens. The local antigen presenting cells (APC) detect antigens found within the anterior chamber of the eye and carry them to the thymus and spleen to create a central tolerance to the retinal antigen. Antigen-specific regulatory T cells are also produced to impair reactive cell responses (57). The blood retinal barrier (BRB) is another mechanism the eye uses to limit its immune reactivity. The endothelial cells of the retinal microvasculature are non-fenestrated and form tight junctions to prevent the passage of any large molecules or cells from the choroid to the retina. Likewise, the tight junctions between the RPE cells work as part of the BRB to maintain the homeostasis by controlling the transport of nutrients, waste, and ions between the photoreceptors and the choroid (58, 59). The eye also lacks lymphatic drainage pathways to limit the movement of leukocytes and antigens (60). In addition to physically limiting the access of immune cells, many ocular cells have properties designed to suppress the immune response. For example, many ocular cells either lack or have a low expression of the major histocompatibility complex (MHC) class 1 α protein to inhibit the activation of T cells. Many ocular cells also constitutively express the Fas ligand, which will trigger apoptosis in any lymphoid cells expressing the Fas receptor. Furthermore,

many immunomodulating proteins are expressed in the eye, such as complement-inhibiting proteins and anti-inflammatory cytokines like the membrane attack complex inhibitory protein (MAC-IP/CD59), and transforming growth factor β (TGF- β) (56, 60, 61).

Due to the immune separation of the eye from the rest of the body, the eye contains its own immunocompetent cells. The two predominant cells with critical immune functions are the retinal pigment epithelial (RPE) cells and microglial cells. The RPE is a single layer of cells between the photoreceptors and choroid, it performs many critical functions aside from being part of the BRB. The RPE acts as an attachment site, binding the rest of the retina to the choroid. It phagocytizes the shed discs from the photoreceptor cells, and it is involved in the retinoid cycling process needed to maintain visual function. Furthermore, the melanin pigment found within the RPE absorbs the excess scattered light in the eye to prevent damage to the retina (59). Moreover, the RPE plays a significant role in modulating both the innate and adaptive immune responses in the retina. RPE cells are capable of expressing both MHC class I and II proteins, allowing them to function as APCs in the retina. Additionally, they express a variety of factors including Fc- γ receptors, toll-like receptors (TLR), complement components, growth factors, and a variety of cytokines and chemokines (62-67). In particular, it has been demonstrated that RPE cell will express interleukin (IL)-6, IL-8, and monocyte chemoattractant protein (MCP)-1 as pro-inflammatory cytokines, and interferon (IFN)- β , IL-11, and TGF- β as anti-inflammatory factors (66, 68).

Microglial cells are the primary immunocompetent cell in the retina. They enter the retina early in embryonic development and work to maintain homeostasis as well as functioning at the resident macrophage in the eye (69). Microglia exist in two states, resting and activated. While the microglial cells are in the resting state they have a ramified morphology and are found primarily within the inner retina among the ganglion and bipolar cells (69-71). The microglia remain dormant in this state until they are activated by infectious agents, cellular debris, lipopolysaccharides, or reactive oxygen species (ROS) (69, 72, 73). Once activated, the microglia enlarge to take on an amoeboid shape with enhanced abilities to proliferate, migrate, and phagocytize (69, 74). The microglia also release multiple cytokines and chemokines, which include MCP-1, IL-1 β , IL-10, IFN- γ , macrophage inflammatory protein (MIP)-1 α , and tumor necrosis factor (TNF)- α . The activated microglial cells will also produce neurotoxic factors including hydrogen peroxide and superoxide anion (75, 76). If the activating stimulus is readily removed, the microglia will return to their resting state; however, if the stimulus cannot be easily removed the microglia will adhere to the surface of the nearby neurons and begin to continuously produce the aforementioned factors, eventually causing the death of the neurons. The cellular debris created from the dying neurons along with this constant production of constituents activates and recruits additional microglia to the site causing neuroinflammation (69, 75). The excessive production of cytotoxins from the prolonged activation of microglial cells has been linked to neurodegeneration in many diseases including experimental herpes encephalitis, West Nile Virus

encephalitis, Parkinson's disease, Huntington's disease, and amyotrophic lateral sclerosis (77-81). Moreover, in the retina, the activation and infiltration of microglial cells has been associated with the retinal degeneration observed in light induced retinal injury and multiple forms of inherited retinal degeneration, including RP (82-84).

Inflammation

The term "Retinitis Pigmentosa" was first used by the Dutch ophthalmologist Dr. Franciscus Donders in 1857 to describe an ocular disorder that presented with night blindness and developed characteristic black pigment deposits on the retina. As the word retinitis is defined as "inflammation of the retina," it was originally believed that inflammation was a key factor in the pathogenesis of the disease (85). For decades, studies have suggested that an immune response may be involved in RP. In 1962, serum samples from six of ten RP patients showed elevated levels of IgM antibodies in circulation (86). Again in 1973, a similar study found significantly increased concentrations of IgM in 52 RP patients compared to 40 non-diseased patients (87). Moreover, a study performed in 1980 by Brinkman *et al.* demonstrated that patients with RP had an immunological response to retinal antigens while non-diseased patients did not. When Brinkman *et al.* exposed the RP patients' blood samples to human retinal antigens or bovine rod outer segments, leukocytes migration, complement fixation, and lymphocyte activation was observed (88). Additionally, in 1988, macrophages, B cells, and various subsets of T cells were found in the vitreous

fluid of three biopsy samples and eight postmortem samples from RP patients. In each of the samples, two-thirds of the immune cells were found to be reactive, whereas the immune cells in the vitreous fluid from non-diseased eyes, which contained only a few macrophages, were mostly non-reactive (89). However, due to the heterogeneity of the disease, there were also reports that found no significant indication of inflammation. Because of these discrepancies, as the genetic mutations behind RP were discovered, it was generally accepted that the genetic defects were the primary cause of RP and the term “retinitis” was a misnomer (85).

Nevertheless, recent studies indicate that inflammation may play a key role in the pathogenesis of retinal degenerative diseases. Multiple studies performed in the 21st century have observed that the secretion of pro-inflammatory cytokines and chemokines is integral in the pathogenesis of several retinopathies including macular edema, age-related macular degeneration (AMD), and diabetic retinopathy (90-93). Furthermore, during the examination of postmortem donor eyes from patients with AMD, late-onset retinal degeneration, and RP, large accumulations of activated microglia were detected within regions of the outer nuclear layer (ONL) where photoreceptor degeneration was occurring (83). These observations have prompted several researchers to once again investigate the relationship between inflammation and disease progression in RP.

The *rd* mouse is a widely used animal model of RP. Using this model, Zeng *et al.* measured the production of mRNA and pro-inflammatory factors

throughout the course of photoreceptor degeneration. It was observed that just prior to the peak of cell death, there was a significant increase in the production of MCP-1, MCP-3, MIP-1, MIP-1 β , regulated on activation normal T cell expressed and secreted (RANTES), and TNF- α . The chemokines caused the activation and migration of microglial cells that released the TNF- α in the ONL (94). Likewise, a study using porcine retinal explants treated with the phosphodiesterase 6 (PDE6) inhibitor Zaprinast as a new model of RP, noticed that an increased production of IL-6 and TNF- α was associated with the photoreceptor cell death (61). In a study using S334ter-4 rats, which have a mutation resulting in a truncated form of rhodopsin, a low dose of the synthetic corticosteroid fluocinolone acetonide (FA) was shown to mitigate the photoreceptor degeneration and preserve visual function. Intravitreal administration of 0.2 μ g/day of FA, attenuated the ERG amplitude loss by 85%. ONL thickness was preserved by 25.8% compared to the controls (six to eight cell rows versus three to four rows at 12 weeks), and there was a seven to eight times reduction in the presence of activated microglial cells in the photoreceptor cell layer (70). Similar results were observed in *CCL3^{-/-}MERTK^{-/-}* mice. *MERTK^{-/-}* mice are a murine model of RP, and the *CCL3^{-/-}MERTK^{-/-}* mice are unable to produce CCL3, also known as MIP-1 α , which is necessary for the recruitment and activation of polymorphonuclear leukocytes. The lack of CCL3 preserved the ONL thickness, decreased the number of microglial and macrophage infiltrates, and increased the BRB integrity by 50% compared to the dystrophic *MERTK^{-/-}* mice (71).

In further support of inflammation playing a pivotal role in the pathogenesis of RP, a set of studies performed by Yoshida *et al.* examined the characteristics of the inflammatory response in both humans with RP and a murine model (95, 96). In the clinical study, 371 RP patients and 165 control patients were examined. A slit-lamp biomicroscope analysis was used to count the number of cellular infiltrates present in the anterior vitreous cavity and compare it to a retrospective analysis of the patient's visual function. It was found that while only two of the controls (1.21%) had five-to-nine cells per field in their eyes, 37.3% of the RP patients had five-to-thirty cells per field, with the younger patients commonly having the higher numbers. The RP patients with five or more cells per field had significantly lower visual function scores compared to both the control patients and RP patients with less or no cells in their anterior vitreous cavity. Biopsies were also taken from the aqueous and vitreous humors of all patients. It was observed that all RP patients had significantly elevated levels of IL-8, MCP-1, and thymus and activation-regulated chemokine (TARC). In addition, IL-6 was detected in 14 out of 16 RP samples while none was detected in any control samples. In the vitreous humor, IL-1 α , IL-1 β , IL-2, IL-4, IL-6, IL-8, IL-10, IFN- γ , growth regulated oncogene- α , I-309, IFN- γ inducible protein (IP)-10, MCP-1, MCP-2, and TARC were all significantly elevated in the RP patients compared to the control patients (95). Taken together, these results suggest chronic inflammation occurs in RP and is related to its pathogenesis.

To further investigate the role of inflammation, Yoshida *et al.* followed this clinical study up with a laboratory study using the rd10 mouse model of RP (96).

It was observed from real time polymerase chain reaction (PCR) of the RNA in the total retinal tissue that MCP-1, IL-1 β , RANTES, and TNF- α were significantly upregulated by postnatal day (p)14, which is prior to the start of photoreceptor cell loss, and maintained throughout the disease course. Immunohistochemistry revealed that increased accumulations of Iba1+ activated microglial cells were found in the subretinal space, ONL, and outer plexiform layer of rd10 retinas at p14 and p21, while the retinas of wild type mice displayed none (96). Collectively, the results of these studies demonstrate that the inflammatory response has an integral role in the degeneration of photoreceptors in RP. Therefore, it can be hypothesized that a treatment which is able to ameliorate the inflammation would be beneficial to patients with RP.

Photobiomodulation

The use of specific wavelengths of light to induce biological changes in cells is known as photobiomodulation (PBM) (97). It has been hypothesized that far-red to near infrared (NIR) light (630-900nm) interacts with cytochromes in the mitochondrial electron transport chain, triggering a cascade of intracellular events culminating in improved cell survival. Cytochrome c oxidase (CcO) is the most likely candidate to be this photoacceptor molecule, as the action spectrum for the cellular effects of PBM corresponds to the absorption spectrum of CcO (98-101). Nitric oxide (NO) competitively binds to CcO in mitochondria, replacing the oxygen normally bound, and thereby inhibits mitochondrial respiration (98, 99, 102). When the NIR light reacts with CcO, it induces a conformational change

which causes the NO to disassociate from the CcO resulting in an increased production of adenosine triphosphate (ATP). The released NO has been postulated to trigger the activation of gene transcription factors that regulate the transcription of genes involved in many cellular functions, including apoptosis and inflammation (98-103).

PBM has been shown to help promote healing, induce cell growth and survival, and reduce inflammation for a variety of conditions. For example, a study done by Muili *et al.* in 2012 treated C57BL/6 mice with experimental autoimmune encephalomyelitis (EAE), a murine model of multiple sclerosis, with 670nm light and found that the disease was ameliorated. Evidence from quantitative real-time PCR suggested that the 670nm light modulated the disease by up-regulating the anti-inflammatory cytokines IL-10 and IL-4, while down-regulating the pro-inflammatory cytokines IFN- γ and TNF- α (104). Similarly, in a study performed by Assis *et al.*, low-level laser therapy was used to treat muscle cryolesions, and it was observed to both significantly reduce oxidative stress and inflammation by modulating the gene expression of *NF- κ B* and *COX-2* (105). Another example is a study that used 810nm light to treat rheumatoid arthritis. The treatment not only showed an improvement in the arthritis, but a decrease in the intracellular levels of TNF- α , IL-1 β , and IL-8 (106). These studies are just a few examples of different conditions in which PBM has been demonstrated to ameliorate disease manifestations. It is likely that PBM may be successfully used to ameliorate RP as well.

Supporting this theory, several studies using PBM on retinopathies have been performed with promising results. For instance, 670nm light has been used to treat methanol-induced retinal toxicity in male Long-Evans rats. The methanol intoxication results in retinal dysfunction and morphological changes in the photoreceptors. Treatment with 670nm light (4.5 J/cm^2) for 144 seconds at five, 24, and 50 hours after intoxication prevented the loss of retinal function and histopathological changes associated with methanol intoxication (98). The treatment of light-induced photoreceptor degeneration with 670nm light under several different conditions (3 min/day at 5 J/cm^2 for 2, 5, 7, or 10 days prior to light-injury, or 3 min/day at 9 J/cm^2 for 5 days either prior, during, or after light-injury) has been shown to be neuroprotective. The treatments attenuated the histological changes associated with the light damage, increased photoreceptor cell survival and function, reduced the production of the stress-related molecule glial fibrillary acidic protein (GFAP), modulated the production of neuroprotective proteins, and decreased the inflammatory response (97, 107). In a study of Retinopathy of Prematurity, which causes retina degeneration due to abnormal vascular development in premature babies, 670nm light (3min/day, 9 J/cm^2) during hyperoxic exposure normalized retinal vascular development and significantly prevented photoreceptor cell death in oxygen-induced retinopathy mouse and rat models (108). In another PBM study performed by Kokkinopoulos *et al.*, 670nm light set at 40 mW/cm^2 was used to treat age-related retinal inflammation, and it was observed to significantly reduce inflammation, the production of $\text{TNF-}\alpha$, and the inflammatory markers complement component 3d

and calcitonin (109). Similar results were observed by Begum *et al.* when using 670nm to treat a complement factor H knockout murine model of AMD. In this study, 670nm light (6mins twice a day for 14 days, at 20 mW/cm²), used as part of the environmental lighting produced a significant reduction in the expression of complement component C3, the stress markers GFAP and vimentin, and increased the expression of CcO (101). Moreover, when 830nm light (3mins/day, 25 mW/cm², 4.5J/cm²) was used to treat the P23H rat model of RP during the peak time of photoreceptor loss, it was shown to attenuate the severity of the disease. The animals treated with the 830nm light had 50% greater ERG amplitudes for both rod and cone response, representing a significant preservation of retinal function. In addition, histological assessments demonstrated that the 830nm light protected against the loss of photoreceptor cells in the retina (110). Collectively, these studies provide considerable evidence to support the application of NIR PBM as a viable treatment option for RP. PBM could be used to delay or prevent the loss photoreceptor cells by modulating the inflammation response, reducing cell stress, and upregulating neuroprotective factors. PBM may offer a non-invasive treatment option for patients that is independent of inheritance pattern and can be effectively initiated after the disease is diagnosed and photoreceptor degeneration has already begun.

II. Hypothesis and Specific Aims

RP is the most common cause of blindness in developed countries, affecting approximately 1 in 4,000 people worldwide (1-5). Evidence suggests chronic inflammation in the retina is a key factor in the pathogenesis of RP, resulting in the degeneration of the photoreceptor cells (86-96). Currently, there is no known treatment or preventive measure to halt the loss of photoreceptor cells in RP. PBM offers a possible method to treat RP as it has been shown to alleviate inflammation and preserve photoreceptor cell morphology and function in other retinopathies (97, 98, 101, 107-109). Recent studies in the P23H rat model of RP have shown that treatment with 830nm light significantly attenuated photoreceptor degeneration and protected against the loss of visual function (110). Considerable evidence supports the modulation of cytokine and chemokine expression as a primary mechanism by which PBM mitigates inflammation (104-106); thus it is likely that NIR light treatment attenuates photoreceptor degeneration by up-regulating anti-inflammatory mediators and down-regulating pro-inflammatory mediators. The overall goal of this study is to determine the anti-inflammatory actions of 830nm light in the P23H rat model of RP.

The hypothesis of this study is that *treatment with 830nm light promotes an anti-inflammatory environment in the retina*. The specific aims listed below were designed to test this hypothesis.

- 1. Compare the concentrations of pro-inflammatory mediators in the retinas of non-dystrophic SD rats with P23H rats and determine the effect of 830nm light on pro-inflammatory mediators in the retina of SD and P23H rats.** The working hypothesis for this specific aim is that *there are differences in the pro-inflammatory mediators in the retinas of P23H and SD rats and that treatment with the 830nm light will reduce the retinal concentrations of pro-inflammatory mediators.*
- 2. Compare the concentrations of anti-inflammatory mediators in the retinas of non-dystrophic SD rats with P23H rats and determine the effect of 830nm light on anti-inflammatory mediators in the retina of SD and P23H rats.** The working hypothesis for this specific aim is that *there are differences in the anti-inflammatory mediators in the retinas of P23H and SD rats and that treatment with the 830nm light will increase the retinal concentrations of anti-inflammatory mediators.*

CHAPTER 2: MATERIALS AND METHODS

I. Animal Model

Male and female Sprague-Dawley (SD) rats were obtained from Harlan Sprague Dawley Inc. (Madison, WI). The albino SD rats were used as non-dystrophic controls for retinal degeneration. Male and female homozygous P23H transgenic rats were provided by the Retinal Degeneration Rat Model Resource at the University of California, San Francisco. The homozygous P23H transgenic rats were crossbred with the SD rats to produce heterozygous P23H transgenic rats. The P23H transgenic rat is a widely accepted model RP as it bears a single amino acid substitution at codon 23, which results in photoreceptor degeneration similar to humans with RP caused by the autosomal dominant P23H mutation (111). Heterozygous P23H rats are used instead of homozygous P23H rats because they more accurately reflect the human genetic condition and disease development, and the rate of retinal degeneration has been well defined for heterozygous P23H rats (112).

All animals were bred and housed in the American Association for Accreditation of Laboratory Animal Care approved facility in Lapham Hall at the University of Wisconsin-Milwaukee. The animals were housed in an environment which is humidity controlled and maintained at 21°C. The animals were provided with food and water *ad libitum* and kept in a dim 12 hour light-and-dark cycle, with an average of illuminance of 5-10 lux. All procedures were approved by the Institutional Animal Care and Use Committee of the University of Wisconsin-

Milwaukee and were conducted in compliance with the Association for Research in Vision and Ophthalmology Statement for the Use of Animals in Ophthalmic and Visual Research.

II. Near Infrared Light Treatment

Previous studies have demonstrated that using the wavelength of 830nm was effective at attenuating the degeneration of photoreceptor cells (110). For this reason, a wavelength of $830\pm 10\text{nm}$ from a Gallium/Aluminum/Arsenide (GaAlAs) light-emitting diode (LED) array (QDI, Barneveld WI) was used for treatment. The treatment was initiated on postnatal day (p) 17, and continued daily until p27. Once per day, rats were placed in a clear polypropylene box with the LED array placed on top. Each treatment consisted of $830\pm 10\text{nm}$ irradiation for 180 seconds at a light intensity of $25\text{mW}/\text{cm}^2$ resulting in a dose, or fluence, of $4.5\text{J}/\text{cm}^2$. This dose of fluence of light has been documented to attenuate the production of inflammatory cytokines in other disease models (98, 104). Treatment controls were sham-treated by being restrained for 180 seconds in the box with the array placed on top, but not exposed to the 830nm light.

III. Tissue Collection

The rats were euthanized at p30 by CO_2 inhalation. Whole eyes and retinas were collected from the rats immediately after euthanasia. Enucleated eyes were punctured with a pointed scalpel at the corneal limbus and

immediately immersed in 4% paraformaldehyde in 0.1 M phosphate-buffered saline (PBS). The eyes were stored in the 4% paraformaldehyde overnight, then transferred to a 4% sucrose solution in 0.1 M PBS and stored at 4°C. From the non-enucleated eye, retinas were harvested. Eyes were held with a forceps at the optic nerve while a 3-5mm incision was made in the corneal limbus. By pulling the forceps from the optic nerve to the cornea, the retina was extracted from the eye and immediately flash frozen in liquid nitrogen. The retinas were stored at -80°C prior to analysis.

IV. Evaluation of Protein Concentration

Three or four retinas were pooled per sample. Each sample was suspended in lysis buffer (10% protein inhibitor cocktail in PBS). The volume of lysis buffer used was determined by multiplying the total retinal weight by 10 and dividing by the number of retinas pooled. The tissue was then homogenized by sonication. The samples were kept on ice during homogenization and sonicated using a set of two 15 second pulses with a five second rest at 50% amplitude. The samples were checked for uniform homogenization, then centrifuged at 13,000xg for five minutes at 4°C. The supernatant was collected and the pellet discarded. The total protein concentration in each sample was then determined using a Pierce™ Bicinchoninic Acid (BCA) Assay Kit from Thermo Scientific according to the manufacturer's instructions. Each sample was analyzed in a 1:10 and 1:100 dilution with PBS and compared to a standard curve ranging from 0 mg/mL to 2 mg/ml. The absorbance was measured for 570nm.

V. Assessment of Cytokine and Chemokine Concentrations

Retinal samples were collected and homogenized by sonication. Samples were stored at -80°C until the analysis was performed. The concentrations of cytokine-induced neutrophil chemoattractant-3 (CINC-3), IL-1 α , IL-6, IL-13, TNF- α , IFN- γ , IL-4, vascular endothelial growth factor (VEGF), IL-10 and tissue inhibitor of metalloproteinase-1 (TIMP-1) were analyzed using R&D Systems' Magnetic Luminex Screening Assay kit. This assay is a multiplex bead based sandwich enzyme-linked immunosorbent assay (ELISA) designed to quantitate multiple cytokines and chemokines in serum, plasma, and tissue culture supernatants. All procedures were performed according to the manufacturer's instructions. A Bio-Rad Bio-Plex analyzer (Dr. Coburn's Lab, Medical College of Wisconsin) was used to measure the concentration of each cytokine and chemokine in pg/ml. Each sample was replicated, and analyzed compared to a standard curve. The standard curve was constructed using a 3-fold dilution series, with seven standards ranging from a 1:3 dilution to a 1:2,187 dilution. Results were normalized to the total amount of protein in each sample.

VI. Statistics

The data was analyzed using a one-way analysis of variance (ANOVA) followed by the Bonferroni post-hoc test. Alpha was set at 0.05 for all *P*-value calculations to determine statistically significant differences between groups.

CHAPTER 3: RESULTS

I. Rationale

Much is known about the phenotypic presentations of RP and the genetic mutations that cause it. However, very little is known about the mechanisms responsible for the pathology of RP. Although some investigators consider the term “retinitis pigmentosa” to be a misnomer with respect to inflammation being involved in pathogenesis, recent studies have provided evidence that chronic inflammation in the retina is a key factor in initiating and propagating the degeneration of photoreceptor cells in RP (86-96). NIR light has been demonstrated to reduce inflammation and improve visual function and photoreceptor cell survival in several other retinopathies (97, 98, 101, 107-109). Moreover, previous experiments using the P23H rat model of RP have demonstrated that treatment with 830nm light significantly attenuated the loss of visual function and photoreceptor cell degeneration (110). Since PBM has been shown to reduce inflammation by upregulating anti-inflammatory mediators and downregulating pro-inflammatory mediators in various conditions (104-106), it is suspected that the modulation of cytokines and chemokines produced in the retina is a primary mechanism by which the 830nm light reduced the severity of disease in the P23H rat. The purpose of this experiment was to assess the effect of the 830nm light on the concentration of inflammatory mediators found in the P23H rat retina. However, since inflammation in this model of RP has not been previously characterized, any differences in the retinal concentrations of the

inflammatory mediators in the P23H rat compared to the non-dystrophic Sprague-Dawley rat were assessed first. Characterization of the inflammatory cytokines and chemokines associated with disease in this model may lead to possible potential therapeutic strategies for the treatment of RP.

The retinal concentrations of the following pro-inflammatory and anti-inflammatory mediators were determined in this study because they have been either implicated as major immune regulators in the rat eye or shown to be significantly elevated in other models of RP:

1) Cytokine-Induced Neutrophil Chemoattractant (CINC)-3: Also known as MIP-2, CINC-3 is a pro-inflammatory chemokine of the CXC subfamily. Its human analog is known as growth regulated oncogene (GRO) of the IL-8 family. As its name suggests, CINC-3 is the primary neutrophil chemotactic factor found in rats, resulting in the infiltration of neutrophils at sites of inflammation. It is primarily produced by monocytes and macrophages, but has also been shown to be produced by epithelial cells (113, 114). Moreover, the acute intraocular inflammation caused by endotoxin induced uveitis in Lewis rats has been associated with increased concentrations of CINC in the serum and aqueous humor (142).

2) Interleukin (IL)-1 α : IL-1 α is a pro-inflammatory cytokine produced by macrophages and epithelial cells. It is known to cause T cell and macrophage activation and has been shown to stimulate the production of other pro-inflammatory factors, such as IL-1 β and granulocyte-macrophage colony stimulating factor in RPE cells (115, 116).

3) IL-6: IL-6 is a pro-inflammatory cytokine produced by T cells, macrophages, endothelial cells, and in the retina, Müller glial cells, and RPE cells. It is known to have a wide range of effects on the inflammatory response. In particular, it stimulates the proliferation and differentiation of B and T cells, and triggers the production of acute phase reactants. The production of IL-6 has been associated with the pathogenesis caused by chronic inflammation in a variety of diseases, including RP (61, 95, 115, 117).

4) Tumor Necrosis Factor (TNF)- α : TNF- α is a pro-inflammatory cytokine produced by macrophages, natural killer (NK) cells, and T cells. TNF- α has multiple functions in the immune response, including stimulating the proliferation, differentiation, and survival of immune cells, mediating cytotoxic effects, and increasing vasodilation and vasopermeability. In the retina, it has been shown to be produced primarily by glial cells and has been associated with retinal degeneration in multiple retinopathies, such as glaucoma, AMD, RP, and ischemic retinopathy (61, 91, 92, 94, 96, 118, 119).

5) Interferon (IFN)- γ : IFN- γ is a pro-inflammatory cytokine that is produced by CD4⁺ T_H1 cells, CD8⁺ T cells, and NK cells. The primary role of IFN- γ is to activate macrophages, but it also increases MHC expression, antigen processing, and Ig class switching, and suppresses T_H2 cells. IFN- γ is generally not present in the ocular tissues of healthy eyes, and its presence has been associated with many ocular diseases. It

has been observed to cause intraocular cellular infiltration, microglia cell proliferation, and photoreceptor cell death (115, 120).

6) Vascular Endothelial Growth Factor (VEGF): VEGF is a protein produced by a variety of cells that stimulates vaculogenesis and angiogenesis. In the retina, VEGF is primarily produced by RPE cells. The production of VEGF is often induced by hypoxic conditions in order to restore adequate oxygen supply to the cells. However, the overexpression of VEGF has been shown to cause vascular leakage and neural retina degeneration, implicating it in retinal diseases like AMD, diabetic retinopathy, and RP (121, 122).

7) IL-4: IL-4 is an anti-inflammatory cytokine produced by CD4⁺ T_H2 cells, mast cells, and basophils. It is involved in regulating the T_H2 immune response by promoting the differentiation of T_H2 cells instead of T_H1 cells from naïve T cells. IL-4 also drives the antibody response by helping to initiate the proliferation and clonal expansion of B cells. A recent study using murine models has demonstrated that IL-4 is primarily expressed in the eye by RPE, choroid, and scleral cells. It was also shown that IL-4 had the ability to suppress the proliferation of retinal progenitor cells and promote their differentiation into rod photoreceptor cells in neonatal mice (115, 123).

8) IL-13: IL-13 is an anti-inflammatory cytokine produced by T_H2 cells. Like IL-4, IL-13 promotes the growth and differentiation of B cells and inhibits the differentiation of T_H1 cells. Moreover, it also inhibits the

production of pro-inflammatory mediators such as IL-1, IL-6, TNF- α , IL-8, and MIP-1 α from macrophages and monocytes. In addition, treatments with IL-13 have been shown to reduce inflammatory in rat models of acute ocular inflammation (115, 124).

9) IL-10: IL-10 is an anti-inflammatory cytokine produced by monocytes, macrophages, and T cells. Together with IL-4, IL-10 promotes the T_H2 cell response instead of the T_H1 cell response. In addition, IL-10 can inhibit the expression of pro-inflammatory mediators from other cells. Studies have shown that in the retina, photoreceptor cells are capable of producing IL-10 in response to IL-27 produced by microglia cells. Furthermore, endogenous and exogenous IL-10 has been observed to reduce inflammation in uveitis (125, 126).

10) Tissue Inhibitor of Metalloproteinase (TIMP)-1: TIMP-1 is a glycoprotein which inhibits the matrix metalloproteinase (MMP)-9. MMPs are endopeptidases capable of degrading extracellular matrices. In the retina, TIMP-1 is found in the interphotoreceptor matrix, which is between the photoreceptors and RPE, and it is suggested that RPE cells may be responsible for the secretion of TIMP-1. In multiple retinal degenerative diseases, TIMP-1 has been observed to be significantly increased. Furthermore, intravitreal injections of TIMP-1 in a S334-ter-line-3 rat model of RP demonstrated that TIMP-1 is capable of helping to restore the homogeneity of photoreceptors in the retina by preventing the formation of

photoreceptor rings around areas of cell death and causing the remaining photoreceptors to be evenly spaced throughout the retina. (127, 128).

II. Compare the concentrations of pro-inflammatory mediators in the retinas of non-dystrophic SD rats with P23H rats and determine the effect of 830nm light on pro-inflammatory mediators in the retina of SD and P23H rats.

Concentrations of Pro-Inflammatory Mediators in the P23H Rat Retina

The retinal concentrations of six pro-inflammatory mediators were measured: CINC-3, IL-1 α , IL-6, TNF- α , IFN- γ , and VEGF. No statistically significant differences were observed between the P23H retina and the SD retina. However, we saw trends that were opposite of what we anticipated. Retinal concentrations of five of the six pro-inflammatory mediators were lower in the P23H rat than the SD rat. The average IL-6 retinal concentration was 813 pg/mL/mg retinal protein in the SD rat, while it was 683 pg/mL/mg retinal proteins in the P23H rat (16% less) (Figure 1). Likewise, TNF- α was found at an average concentration of 96 pg/mL/mg retinal protein in the SD rat and 79 pg/mL/mg retinal protein in the P23H rat (18% less) (Figure 2). Somewhat greater differences were observed in the mean retinal concentrations of IFN- γ , VEGF, and CINC-3. Retinal concentrations of IFN- γ and VEGF were 29% and 36% lower, respectively, in the P23H retina compared to the SD retina (268 pg/mL/mg

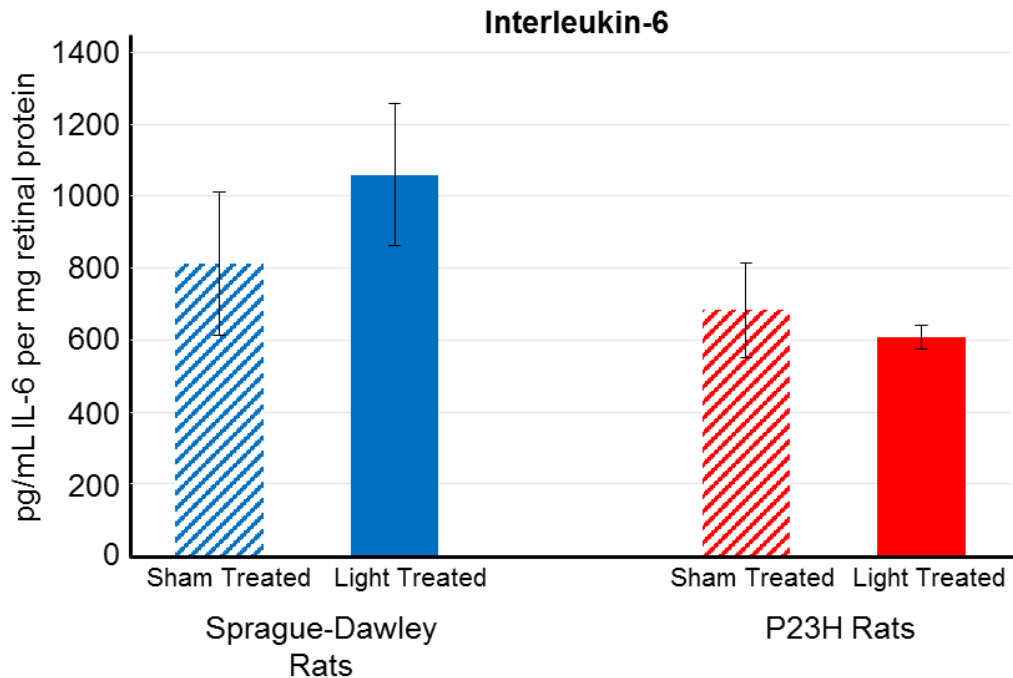


Figure 1. Concentration of IL-6 found in retinal samples of sham treated Sprague-Dawley rats (n=4), 830m light treated Sprague-Dawley rats (n=5), sham treated P23H rats (n=5), and 830nm P23H rats (n=6). Retinal samples were obtained at p30. Error bars indicate SEM. No statistically significant differences ($P < 0.05$).

retinal protein vs. 192 pg/mL/mg and 90 pg/mL/mg vs 137 pg/mL/mg) (Figures 3 and 4). Of all the pro-inflammatory mediators, CINC-3 showed the greatest difference. The mean concentration of CINC-3 in the P23H retinas was 52% lower than that measured in the SD retina (26 pg/mL/mg retinal protein vs. 54 pg/mL/mg) (Figure 5). IL-1 α was the only cytokine of the six pro-inflammatory mediators measured to have a higher mean retinal concentration in the P23H rats. However, the average IL-1 α concentration was still nearly identical in the retinas of the two animals, as the P23H rat had only a 5% increase compared to the SD retinal concentration (120 vs. 115 pg/mL/mg retinal protein) (Figure 6).

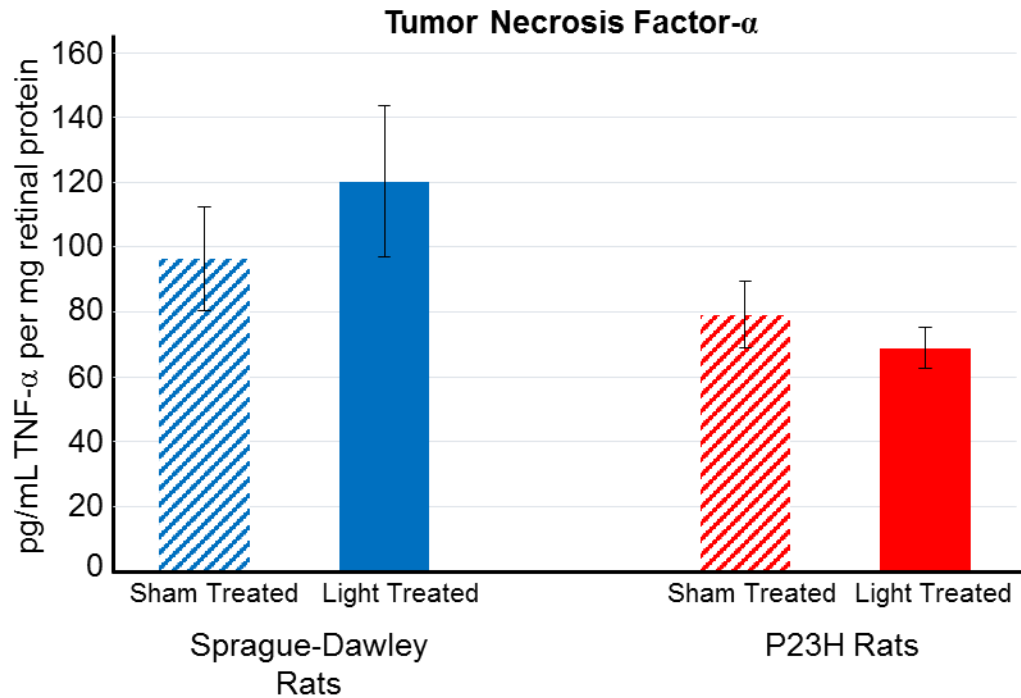


Figure 2. Concentration of TNF- α found in retinal samples of sham treated Sprague-Dawley rats (n=4), 830m light treated Sprague-Dawley rats (n=5), sham treated P23H rats (n=5), and 830nm P23H rats (n=6). Retinal samples were obtained at p30. Error bars indicate SEM. No statistically significant differences ($P < 0.05$).

Effects of 830nm Light on Retinal Concentrations of Pro-Inflammatory Mediators

No significant differences were observed in the retinal concentrations of the pro-inflammatory mediators between the sham treated and 830nm light treated rats. The standard error of the mean was large for each mediator measured, due to the small sample sizes used. The changes observed due to the 830nm light treatment were very minor, as the greatest reduction was only 13% with TNF- α (Figure 2). IL-6 was reduced by 11%, and VEGF was 4% less in the light treated P23H rats compared to the sham treated (Figures 1 and 4). IL-1 α displayed no differences with the light treatment, as the average retinal concentration remained at 121 pg/mL/mg retinal protein (Figure 6). Similarly, the

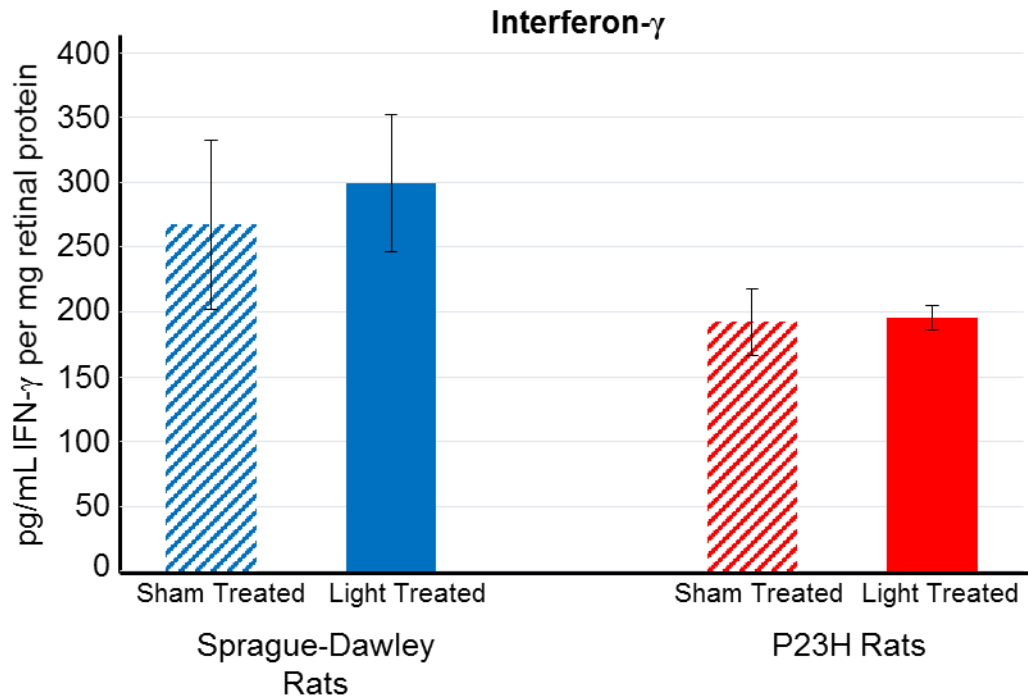


Figure 3. Concentration of IFN- γ found in retinal samples of sham treated Sprague-Dawley rats (n=4), 830nm light treated Sprague-Dawley rats (n=5), sham treated P23H rats (n=5), and 830nm P23H rats (n=6). Retinal samples were obtained at p30. Error bars indicate SEM. No statistically significant differences ($P < 0.05$).

average retinal concentration of IFN- γ after the 830nm light treatment was only 2% greater than the sham treated P23H rats (Figure 3). CINC-3 was the only pro-inflammatory mediator to be increased by more than a marginal amount with the 830nm light. Its average retinal concentration was 19% greater in the light treated P23H rats compared to the sham treated P23H rats (Figure 5).

In contrast to the P23H rats, the retinal concentrations of all six pro-inflammatory mediators were increased in the SD rats treated with the 830nm light compared to the sham treated SD rats. Still, none of these differences were statistically significant. However, while most of the changes observed between the P23H rats were marginal, the differences between the light treated SD rats

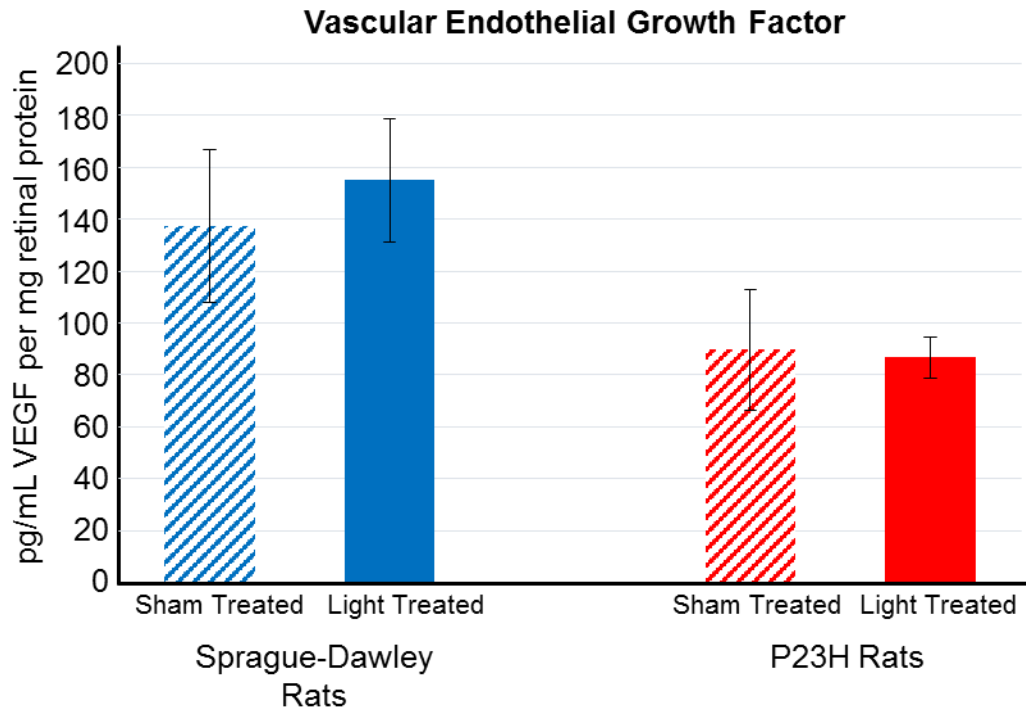


Figure 4. Concentration of VEGF found in retinal samples of sham treated Sprague-Dawley rats (n=4), 830m light treated Sprague-Dawley rats (n=5), sham treated P23H rats (n=5), and 830nm P23H rats (n=6). Retinal samples were obtained at p30. Error bars indicate SEM. No statistically significant differences ($P < 0.05$).

and sham treated rats were generally larger. The increases ranged between 11% and 42% for IFN- γ and TNF- α , respectively (Figures 3 and 2).

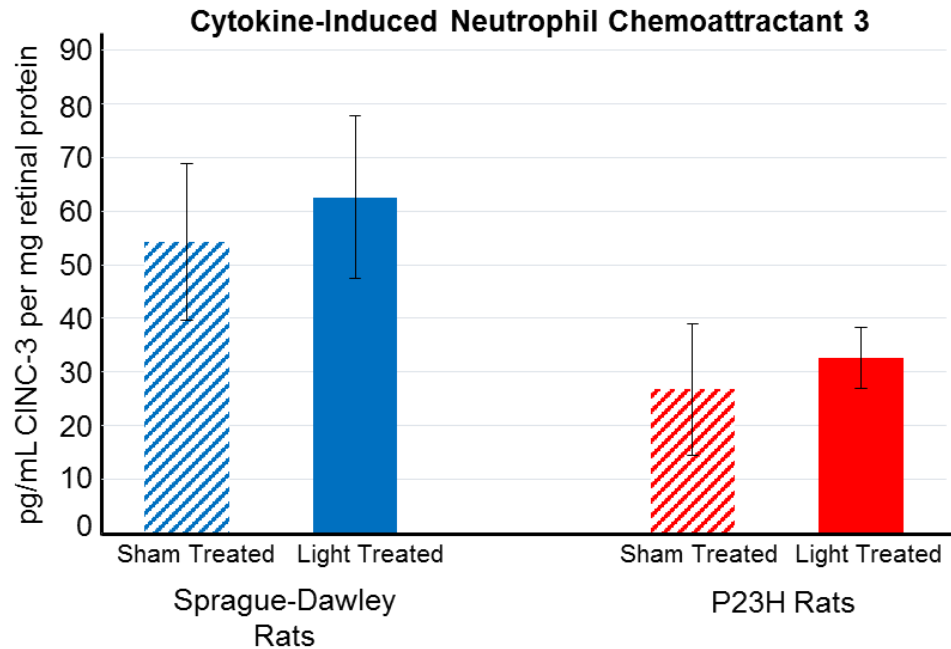


Figure 5. Concentration of CINC-3 found in retinal samples of sham treated Sprague-Dawley rats (n=4), 830m light treated Sprague-Dawley rats (n=5), sham treated P23H rats (n=5), and 830nm P23H rats (n=6). Retinal samples were obtained at p30. Error bars indicate SEM. No statistically significant differences ($P < 0.05$).

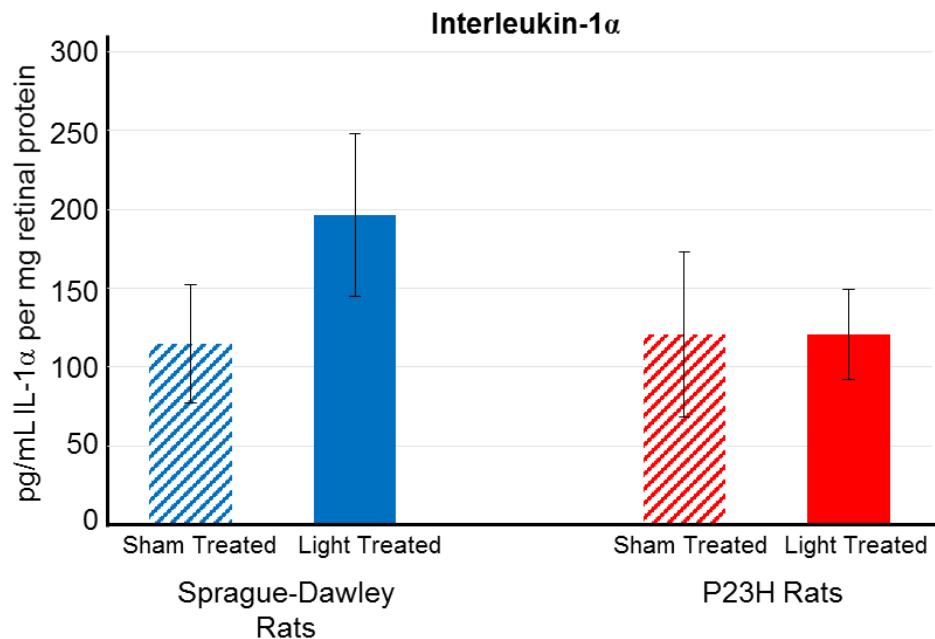


Figure 6. Concentration of IL-1 α found in retinal samples of sham treated Sprague-Dawley rats (n=4), 830m light treated Sprague-Dawley rats (n=5), sham treated P23H rats (n=5), and 830nm P23H rats (n=6). Retinal samples were obtained at p30. Error bars indicate SEM. No statistically significant differences ($P < 0.05$).

III. Compare the concentrations of anti-inflammatory mediators in the retinas of non-dystrophic SD rats with P23H rats and determine the effect of 830nm light on anti-inflammatory mediators in the retina of SD and P23H rats.

Concentrations of Anti-Inflammatory Mediators in the P23H Rat Retina

Four anti-inflammatory mediators were measured with the Magnetic Luminex Screening assay: IL-13, IL-4, IL-10 and TIMP-1. There was no difference between the average P23H and SD retinal concentrations of IL-13, as both contained approximately 39 pg/mL/mg retinal protein (Figure 7). There was 20% more IL-4 present in the P23H retina than the SD retina (26 pg/mL/mg vs. 21 pg/mL/mg) respectively, yet this was not statistically significant (Figure 8).

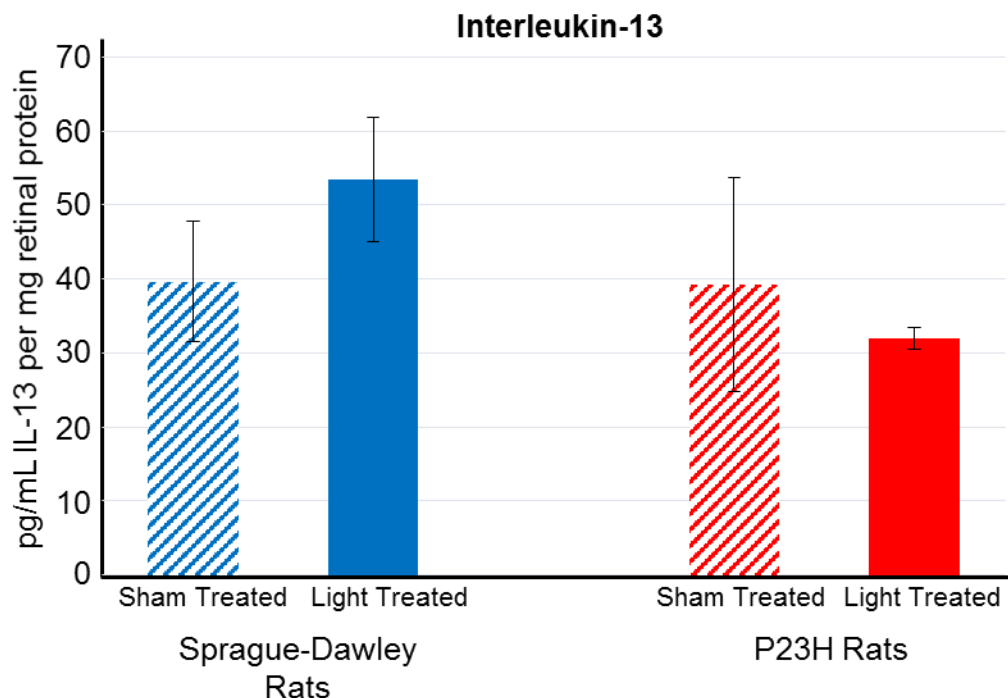


Figure 7. Concentration of IL-13 found in retinal samples of sham treated Sprague-Dawley rats (n=4), 830m light treated Sprague-Dawley rats (n=5), sham treated P23H rats (n=5), and 830nm P23H rats (n=6). Retinal samples were obtained at p30. Error bars indicate SEM. No statistically significant differences ($P < 0.05$).

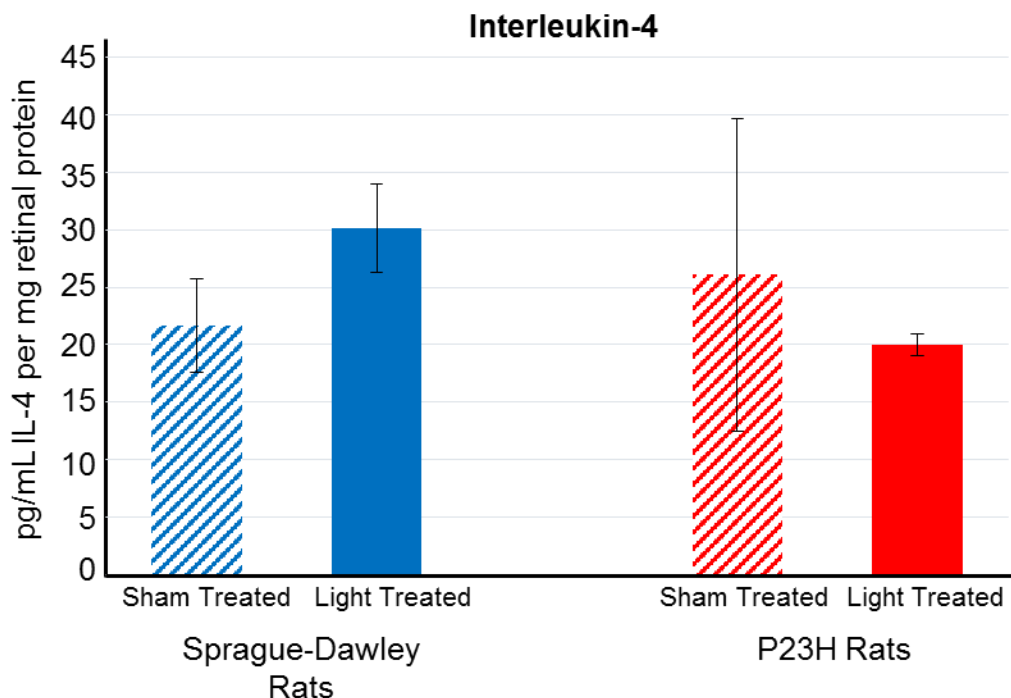


Figure 8. Concentration of IL-4 found in retinal samples of sham treated Sprague-Dawley rats (n=4), 830m light treated Sprague-Dawley rats (n=5), sham treated P23H rats (n=5), and 830nm P23H rats (n=6). Retinal samples were obtained at p30. Error bars indicate SEM. No statistically significant differences ($P < 0.05$).

Likewise, there was no statistically significant difference between the P23H and SD retinal concentrations of IL-10. However, the average P23H retinal concentration of 21.44 pg/mL/mg retinal protein was 33% less than the average retinal concentration of 32 pg/mL/mg retinal protein observed in the SD retina (Figure 9). Conversely, the retinal concentrations of TIMP-1 was significantly greater in the P23H rat compared to the SD rat ($P = 0.008$). The average level of TIMP-1 observed in the P23H retina was 96% greater than what was observed in the SD retina, at 24,357 pg/mL/mg retinal protein compared to 9,234 pg/mL/mg retinal protein (Figure 10).

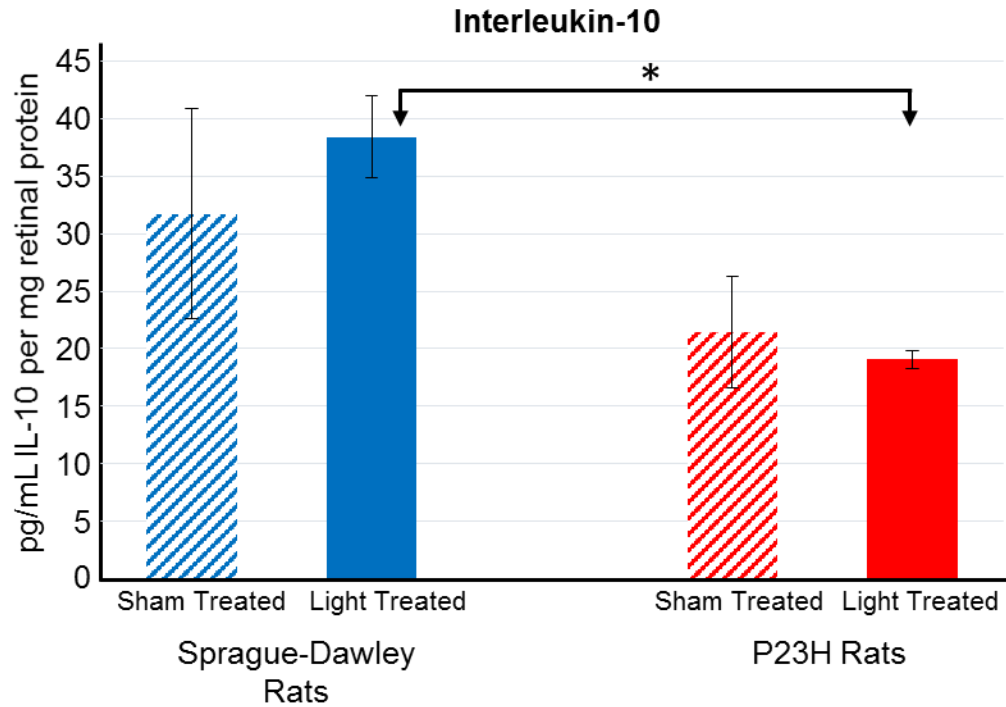


Figure 9. Concentration of IL-10 found in retinal samples of sham treated Sprague-Dawley rats (n=4), 830m light treated Sprague-Dawley rats (n=5), sham treated P23H rats (n=5), and 830nm P23H rats (n=6). Retinal samples were obtained at p30. * denotes a statistically significant difference ($P<0.05$). Error bars indicate SEM.

Effects of 830nm Light on Retinal Concentrations of Anti-Inflammatory Mediators

No significant differences were observed in the retinal concentrations of the anti-inflammatory mediators between the sham treated and 830nm light treated rats. The trends that we observed in the P23H rats indicated that the 830nm light treatment decreased the retinal concentration of all four of the anti-inflammatory mediators. IL-4 displayed the greatest change, with a 24% reduction in the light treated rats compared to the sham treated rats (Figure 8). IL-13 was observed to have a 19% reduction, and IL-10 was reduced by 12% (Figures 7 and 9). TIMP-1 had the least alteration of its retinal concentration

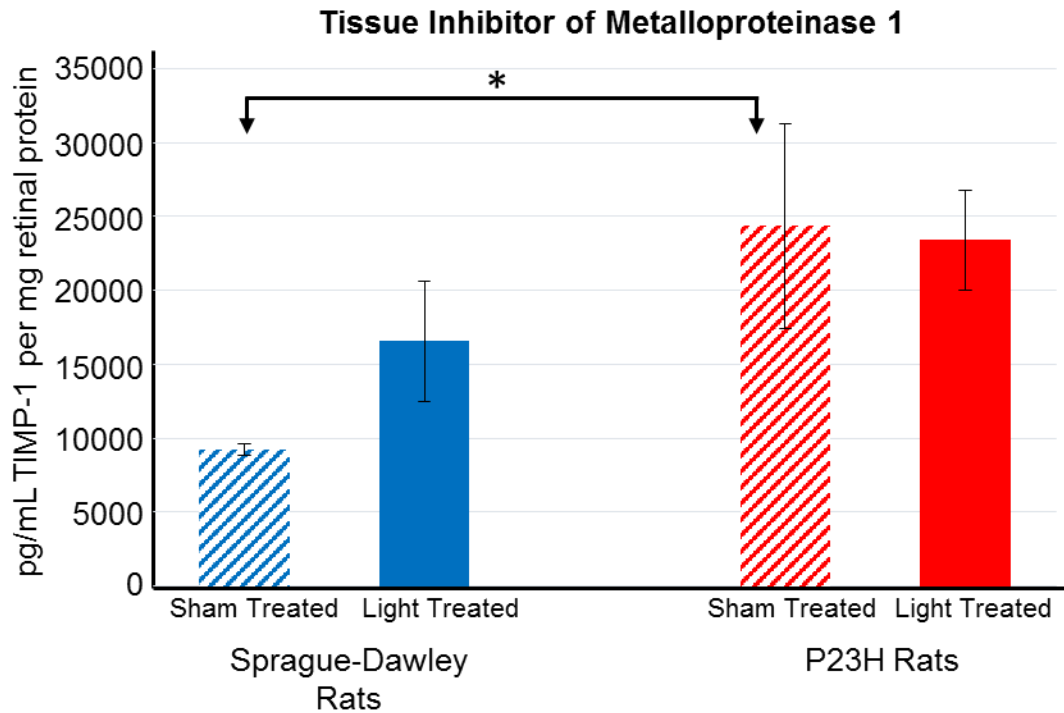


Figure 10. Concentration of TIMP-1 found in retinal samples of sham treated Sprague-Dawley rats (n=4), 830nm light treated Sprague-Dawley rats (n=5), sham treated P23H rats (n=5), and 830nm P23H rats (n=6). Retinal samples were obtained at p30. * denotes a statistically significant difference ($P < 0.05$). Error bars indicate SEM.

caused by the 830nm light treatment, being reduced by only 4% compared to the sham treated P23H rats (Figure 10).

The opposite trends were observed in the SD rats. All of the anti-inflammatory mediators were found to be elevated in the light treated SD rats when compared to the sham treated SD rats. The most notable difference of this group was in the average retinal concentration of TIMP-1, which was observed to be 9,234 pg/mL/mg retinal proteins in the sham treated SD rats and 16,561 pg/mL/mg retinal protein in the light treated SD rats, a 45% increase (Figure 10).

Furthermore, the retinal concentration of IL-10 was found to be significantly greater in the SD light treated rats compared to the P23H light treated rats ($P=0.00028$) (Figure 9).

CHAPTER 4: DISCUSSION

The secretion of inflammatory cytokines and chemokines has been associated with the pathogenesis of multiple retinopathies, including AMD, diabetic retinopathy, and late-onset retinal degeneration (83, 90-93). Following these observations, the concept that inflammation was involved in RP was renewed. PBM, which is the use of light to induce a biological change in cells, has been demonstrated to reduce inflammation for a variety of conditions (98-109). Recent experiments have shown that 830nm PBM is capable of significantly alleviating RP in the P23H transgenic rat model. The 830nm PBM preserved rod and cone ERG responses and prevented the loss of photoreceptor cells (110). However, the mechanism by which the 830nm light attenuated disease is unknown. Since the reduction of inflammation by up-regulating anti-inflammatory mediators and down-regulating pro-inflammatory mediators has been reported in a variety of disease states following PBM (104-106), we hypothesized that the modulation of cytokines and chemokines may be a primary mechanism by which the 830nm PBM ameliorated the degeneration of the photoreceptor cells in the P23H rat. However, the inflammatory profile of the retina of the P23H rat has never been characterized. For this reason, the following specific aims were designed to assess the association of cytokines and chemokines with retinal degeneration in the P23H rat, and determine the effect of 830nm light on the inflammatory mediators in the retina of the P23H rat.

1. **Compare the concentrations of pro-inflammatory mediators in the retinas of non-dystrophic SD rats with P23H rats and determine the effect of 830nm light on pro-inflammatory mediators in the retina of SD and P23H rats.** The working hypothesis for this specific aim is that *there are differences in the pro-inflammatory mediators in the retinas of P23H and SD rats and that treatment with the 830nm light will reduce the retinal concentrations of pro-inflammatory mediators.*

2. **Compare the concentrations of anti-inflammatory mediators in the retinas of non-dystrophic SD rats with P23H rats and determine the effect of 830nm light on anti-inflammatory mediators in the retina of SD and P23H rats.** The working hypothesis for this specific aim is that *there are differences in the anti-inflammatory mediators in the retinas of P23H and SD rats and that treatment with the 830nm light will increase the retinal concentrations of anti-inflammatory mediators.*

I. Compare the concentrations of pro-inflammatory mediators in the retinas of non-dystrophic SD rats with P23H rats and determine the effect of 830nm light on pro-inflammatory mediators in the retina of SD and P23H rats.

Retinas were harvested from the dystrophic P23H rats and the non-dystrophic SD rats at postnatal day (p)30 to compare the retinal concentrations of the selected inflammatory mediators. Interestingly, pro-inflammatory cytokine and chemokine concentrations did not differ between P23H and SD retinas.

Unexpectedly, the concentrations of most of the pro-inflammatory mediators appeared to be slightly lower in the retinas of P23H rats than those of the SD rats. Due to the large variability in individual values and the small sample size, statistical significance was not obtained. The concentrations of two pro-inflammatory mediators, CINC-3 and VEGF, appeared to be substantially lower in the retinal tissue from P23H rats compared to SD rats. The retinal concentration of CINC-3 in the P23H retina was approximately half of that measured in the SD retina. As cellular infiltration of the retina has been one of the most constant observations of previous clinical and laboratory studies of inflammation in RP (70, 71, 83, 95, 96), it was surprising to find that the primary neutrophil chemotactic factor of rats was not elevated. However, while IL-8 and GRO, which are in the same family as CINC-3, have been shown to be significantly elevated in the aqueous and vitreous humors of human patients with RP (95), neither CINC-3 nor MIP-2 have been observed in rat or murine models of RP. Therefore, it is possible that CINC-3 is not involved in the recruitment of microglia or other immune cells infiltrating the retina in this model of RP. Similarly to CINC-3, the concentrations of VEGF in the P23H retinas were one-third less than that measured in the SD retinas. This was also contrary to what we anticipated, as elevated levels of VEGF have been implicated in the pathogenesis of retinal diseases, including AMD, diabetic retinopathy, and RP. For example, the overexpression of VEGF has been demonstrated to cause vascular leakage and retinal degeneration in Royal College of Surgeon (RCS) rats (122). Also, the intravitreal injection of bevacizumab, which is an anti-

angiogenesis drug that suppresses VEGF, into RP patients has been shown to preserve the central macular thickness (121). These results suggest that increased concentrations of VEGF may be associated with retinal degeneration; however, one of the clinical manifestations of RP is the attenuation of retinal arterioles, which becomes progressively more severe as the disease develops (8, 11). Since the primary function of VEGF is angiogenesis (121, 122), the continued attenuation of the retinal arterioles may suggest that while VEGF expression may be involved in the initiation of disease, its expression decreases as the disease progresses. In this experiment, retinal tissues were harvested at p30, after the disease has significantly developed (135). For this reason, the expression of VEGF may have decreased in the dystrophic P23H rats compared to the non-dystrophic SD rats.

In order to assess the effect of the 830nm light on the pro-inflammatory mediators, dystrophic P23H rats and non-dystrophic SD rats were either treated with 830nm light or sham treated for 10 days, starting at p17. Retinal tissue was harvested from the light treated and sham treated rats at p30, and cytokine and chemokine concentrations were measured and compared. No significant differences in the retinal concentrations were detected between sham treated and 830nm light treated rats. Yet, there was a slight reduction in the average retinal concentration of three of the six pro-inflammatory mediators measured. While these differences were minor, because of the small sample size and the timing of the retinal harvest these lowered concentrations may suggest an anti-inflammatory influence of the 830nm light.

II. Compare the concentrations of anti-inflammatory mediators in the retinas of non-dystrophic SD rats with P23H rats and determine the effect of 830nm light on anti-inflammatory mediators in the retina of SD and P23H rats.

The only anti-inflammatory mediator that was observed to be significantly different between the P23H rat and the SD rat was TIMP-1. The retinal concentration of TIMP-1 in the P23H retina was nearly double that measured in the SD retina. This finding partially supports our hypothesis, in that the imbalance of TIMPs and the MMPs they inhibit have been implicated in the pathogenesis of central nervous system inflammatory diseases and retinal degeneration (127, 128, 129). TIMP-1 has additional roles in beyond inhibiting MMPs, such as activating growth factors, inhibiting angiogenesis, promoting cell proliferation, and upregulating anti-apoptotic processes (130). Furthermore, the secretion of MMPs and TIMPs by astrocytes and microglial cells has been shown to be induced by IL-1 β , TNF- α , and lipopolysaccharides during states of inflammation (131). MMPs are often disproportionately elevated compared to the TIMPs, overwhelming the inhibition; however, the elevated expression of TIMP-1 has been suggested as a biomarker for the severity of diseases associated with chronic inflammation. For example, in studies of inflammatory bowel disease and liver fibrosis from chronic hepatitis B, serum levels of TIMP-1 have been demonstrated to be significantly correlated with the degree of inflammation observed in patients (136, 137). Additionally, a study examining the expression of MMPs and TIMPs in experimental autoimmune encephalomyelitis (EAE) found that the expression of TIMP-1 was restricted to activated astrocytes surrounding

inflammatory lesions (129). Therefore, the significant elevation of TIMP-1 in the retinas of the P23H rats may suggest an inflammatory retinal environment.

No differences in concentrations of the anti-inflammatory cytokines IL-4 and IL-13 were observed between the dystrophic P23H retinas and the non-dystrophic SD retinas. The retinal concentration of IL-10 in the P23H rat was one-third less than what was measured in the retina of the SD rat. This difference was not statistically significant; however, due to the small sample sizes and large variability, it may still indicate a potential difference between the P23H and SD retinas. IL-10 is a potent anti-inflammatory cytokine capable of suppressing the expression of multiple pro-inflammatory mediators for macrophages and T_H1 cells, such as IL-1 β , IL-6, IL-8, TNF- α , and IFN- γ (115, 126, 138). Consequently, IL-10 deficiency has been linked to intensified and prolonged inflammation responses in multiple disease states (125, 139, 140, 141). Thus, if the lower retinal concentrations of IL-10 observed in the P23H retinas compared to the SD retinas can be confirmed in future studies with larger sample sizes, it would support our hypothesis by suggesting pro-inflammatory environment in retina of the P23H rat.

It was expected that the 830nm light treatment would increase the retinal concentrations of the anti-inflammatory mediators, but in this experiment it was observed that the concentrations of all four anti-inflammatory mediators were decreased. However, these reductions were not statistically significant. Additionally, the standard error of the mean was extremely large for each mediator measured. Taken together, these results indicate that the 830nm PBM

had no effect on the retinal concentrations of the anti-inflammatory mediators. Interestingly, a significant difference was observed between the light treated P23H rats and light treated SD rats in the retinal concentration of IL-10. This significant difference may support the potential difference between the untreated P23H and SD rats' IL-10 retinal concentrations discussed above. The light treated sample sizes contained one more rat than the untreated sample sizes, this slight increase may have allowed the significant difference to be detected.

III. Discussion

Studies have shown that the peak photoreceptor degeneration in the P23H rat occurs at approximately postnatal day 20 (112, 135). Moreover, the inflammatory response has been shown to precede photoreceptor cell loss (94, 96). Thus, it is possible that we were unable to detect differences in the retinal concentrations of the pro-inflammatory and anti-inflammatory mediators between the P23H rats and the SD rats in our study because we harvested retinal tissue after the peak of inflammation in this model. In the heterozygous P23H rat, the majority of photoreceptors are lost by p60, with the peak of photoreceptor degeneration occurring at approximately p20. At p30 the photoreceptors are still degenerating, but at a significantly slower rate than at the p20 peak (112, 135). If inflammation is a factor in driving the degeneration of photoreceptors in the P23H transgenic rat model of RP, then the production of inflammatory mediators is likely to be predominately occurring prior to, or during, the peak of photoreceptor

cell death. By p30, the immune system may have adapted the chronic inflammation and returned the majority of cytokine and chemokine production to homeostasis in the retina.

This reasoning that the timing of our retinal harvest was too late to observe elevated concentrations of our chosen inflammatory mediators is supported by the evidence provided in the studies performed by Zeng *et al.* and Yoshida *et al.*, which observed the production of pro-inflammatory factors during the disease course of murine models of RP. Zeng *et al.* measured the apoptosis of photoreceptor cells in the *rd* mouse at p8, 10, 12, 14, 16, and 18 and found that the photoreceptor cell death began at p10 and peaked at p16. Additionally, Zeng *et al.* demonstrated that the production of MCP-1, MCP-3, MIP-1, MIP-1 β , RANTES, and TNF- α was significantly increased by p8 and peaked at p12. This corresponded with the activation of microglial cells, which started at p10 and peaked by p14 (94). Likewise, using the *rd10* mouse model of RP, Yoshida *et al.* demonstrated that the retina expression of MCP-1, IL-1 β , RANTES, and TNF- α was significantly upregulated by p14 prior to the start of photoreceptor cell loss. This upregulated expression was maintained throughout the course of the disease; however, the expression of MCP-1 and TNF- α was halved by p17 and continued to decrease through p21 and p28. Similarly, the IL-1 β expression was nearly 10 times less by p17. The retinal expression of RANTES was the only factor measured to increase over time from p17 to p28 (96). Since Zeng *et al.* and Yoshida *et al.* show that the pro-inflammatory mediators were produced mainly before photoreceptor cell death, these results suggest that a better

strategy to assess the role of inflammation in the retinal degeneration of the P23H rat would involve a time course. Additional studies should be performed to establish the time course of cytokine and chemokine expression during the onset and development of disease in the P23H rat. Since the photoreceptor cell loss peaks at p20 in this model of RP, it is suggested the expression should be measured beginning at p5 and again at p10, p15, p20, p25, and p30.

Achieving measurable concentrations of each inflammatory mediator was another difficulty with this experiment that may have masked the effects of the 830nm light. Due to the small size of the rat eye, retinas needed to be pooled in groups of three or four to obtain sufficient concentrations for the screening assay used. This greatly limited the sample size of each group, and may have limited the assay's ability to detect statistically significant differences. In future experiments, quantitative real-time PCR may be used to determine the level of mRNA for each inflammatory mediator. This technique has been used to measure the expression of cytokines and chemokines in the retinas of murine models of RP (94, 96), and may be a more accurate method when dealing with small tissue samples. Also, it is possible that the cytokines and chemokines primarily associated with the retinal inflammation in the P23H rat were not among the 10 factors tested in this experiment. The pro-inflammatory factors MCP-1, IL-1 β , MIP-1, and RANTES are additional potential targets to investigate, as these factors have been shown to be significantly elevated in several murine models of RP as well as patients with RP (71, 94-96).

The finding that the light treatment had no significant effects on the retinal concentrations of the cytokines and chemokines measured is unsurprising due to the minimal signs of inflammation observed at the time examined. If inflammation is not a significant factor in the pathogenesis of the disease, then there is no response for the NIR light treatment to down-regulate. Furthermore, the timing of the retinal harvest may have been inadequate to accurately measure the effect of the 830nm light treatment. As discussed earlier, the majority of the production of pro-inflammatory factors is likely occurring prior to or during the peak of photoreceptor cell loss (94-96). In addition, as demonstrated by Yoshida *et al.* in the rd10 mouse, the expression of inflammatory factors can change rapidly. In the three day period between the initial and next sequential measurement, the retinal expression of MCP-1, TNF- α , and IL-1 β was reduced by half or more (96). Therefore, any significant modulation of the inflammatory response due to the 830nm light treatment is likely occurring in the first half of the 10 day treatment, when the rate of photoreceptor degeneration is highest (112). In order to verify the effect of 830nm PBM, a time course study examining the retinal concentrations prior, during, and immediately after the light treatment is suggested.

There is also the possibility that the 830nm light treatment had no effect on the inflammatory response of the P23H rat. In this experiment, the 830nm light was used in order to replicate the methods used in the previous study using the P23H rat model of RP. However, this wavelength may not be the most effective treatment. While the NIR wavelengths between 630-900nm have been

shown to be reactive with cytochrome c oxidase (CcO) and able to modify cellular functions in order to promote cell growth and survival, the efficacy of each wavelength is different. During the comparison of the absorption spectrum of CcO and its activity after exposure to various far-red and NIR wavelengths, it was demonstrated that wavelengths of 670nm and 830nm both corresponded with the peaks of absorbance and activation (132). For this reason, these two wavelengths have commonly been used for the treatment of various conditions. However, the most effective wavelength and treatment parameters are dependent on the condition, the affected tissue type, and location being treated (102, 133, 134).

A study performed by Giacci *et al.* examined the efficacy of 670nm and 830nm light treatments in four different rat models of central nervous system injury, which included a light-induced retinal degeneration model. It was found that the efficacy of each wavelength varied by the injury type. In the case of the light induced retinal degeneration, it was demonstrated that a five day pre-treatment with 670nm light (3mins/day at $3.4\text{J}/\text{cm}^2$) was able to significantly reduce the amount photoreceptor cell death after injury, but a five day pre-treatment with 830nm light (3min/day at $2.7\text{J}/\text{cm}^2$) was not (134). Additionally, when a reduction of inflammation was observed in other studies using NIR light to treat retinal degeneration, 670nm light was used instead 830nm light (97, 101, 107, 109). Taken together, this suggests that using 670nm light with the P23H rat model of RP may provide a greater effect on the retina's inflammation response than the 830nm light.

In summary, the working hypothesis of aim 1 was that *there are differences in the pro-inflammatory mediators in the retinas of P23H and SD rats and that treatment with the 830nm light will reduce the retinal concentrations of pro-inflammatory mediators*. The data provided by this experiment did not support this hypothesis, as no significant differences in retinal concentrations of the pro-inflammatory mediators were observed between P23H and SD rats; nor were significant differences observed between the 830nm light treated rats and sham treated rats. The working hypothesis of aim 2 was that *there are differences in the anti-inflammatory mediators in the retinas of P23H and SD rats and that treatment with the 830nm light will increase the retinal concentrations of anti-inflammatory mediators*. The data provided by this experiment partially support this hypothesis, as a significant difference between the P23H rat and SD rat in the retinal concentrations of TIMP-1 was observed, which may suggest an inflammatory environment in the retina of the P23H rat. In addition, the retinal concentration of IL-10 was lower in the P23H retinas than the SD retinas, signifying a potential inability to regulate an exacerbated or prolonged inflammatory response occurring in the retina. While this difference was not statistically significant between the untreated P23H and SD rats, it was significantly different between the light treated P23H and SD rats. We suspect that if the sample size was increased, a significant difference would be observed. However, no significant differences were observed in the anti-inflammatory mediators between the 830nm light treated rats and the sham treated rats.

After comparing the experimental design of this study with the design of previous studies examining the production of inflammatory mediators in animal models of RP, we conclude that the timing of the retinal harvest may have been too late to evaluate the expression of inflammatory cytokines and chemokines in the retina of the P23H rat and to observe the effects of the light treatment.

Additional experiments will be needed to establish a time course for the expression of cytokines and chemokines through the disease course of the P23H rat, beginning prior to the start of photoreceptor cell death. Once a time course is established, further experiments with the 830nm light are needed to measure the retinal concentrations of the inflammatory mediators prior to treatment, during treatment, and immediately after treatment in order to verify the effect of 830nm light on the production of inflammatory mediators in the retina of the P23H rat.

CHAPTER 5: CONCLUSIONS AND FUTURE DIRECTIONS

RP is the most common cause of blindness in developed countries, affecting 1 in 4,000 people (1-5). RP was first described in 1857 (85). Since then, the clinical manifestations of the disease have been well characterized and over half the genetic mutations responsible for RP have been identified (1). Despite this, little is known about the mechanisms of the disease. Despite considerable efforts, there are currently no effective treatment or preventative measures for RP. Photobiomodulation using light in the far-red to NIR range of the spectrum has been shown to attenuate inflammation, improve retinal function, and prevent photoreceptor cell death in several other retinopathies (97, 98, 101, 107-109). Recent investigations using the P23H rat model of RP provide evidence that both 670nm and 830nm PBM protect against photoreceptor cell death (110). Taken together, these studies provide considerable evidence to support the application of NIR light as a potential treatment for RP. However, PBM must achieve FDA approval before it will be used to treat patients. In order to gain this approval, the mechanism by which the NIR light functions to ameliorate disease it must be identified. The objective of this thesis to contribute to this knowledge by characterizing the role of retinal inflammation in the pathogenesis of RP and determining if reducing inflammation is a mechanism by which PBM attenuates retinal degeneration.

These experiments tested the hypothesis that *830nm light promotes an anti-inflammatory environment in the retina*. Overall, the hypothesis of this study was only partially supported, as no effects of the 830nm PBM were observed, but

differences seen in the cytokine and chemokine retinal concentrations suggested inflammation is occurring in the P23H rat retina. These results are novel as this is the first study to investigate inflammation in the P23H rat, which is a widely used model of RP. Moreover, the results of this study aid in characterizing the role of inflammation in RP, as not many studies have examined the role of inflammation in the pathogenesis of RP despite its implication in initiation and propagation of other retinal degenerative diseases (90-93). Establishing a role of inflammation in RP allows for the development of potential treatment options for patients by identifying a mechanism that can be manipulated to delay or halt the degeneration of photoreceptor cells. Supporting this idea of targeting inflammation for the treatment of RP, intravitreal injections of fluocinolone acetonide (FA) in several other rat models of retinal degeneration have been able to reduce microglia cell activation and migration, as well as preserve visual function and prevent photoreceptor cell death (70). Therefore, additional experiments comparing the effects of intravitreal FA injections and NIR light treatments in the P23H rat should be performed. In addition to providing evidence that could demonstrate a causal role for inflammation in the pathogenesis of RP, by comparing the results of the NIR light treatment and the FA treatments, the modulation of inflammation may be verified as a mechanism by which NIR light attenuates photoreceptor degeneration in the P23H rat.

In order to fully characterize the inflammatory response in the retina of the P23H rat model of RP and elucidate the protective mechanisms of PBM, future experiments should be designed to evaluate the complete inflammatory pathway.

For example, the presence of cellular infiltrates and the migration of microglia cells from the inner nuclear layer to the outer nuclear layer has been associated with the photoreceptor degeneration observed in both humans and animals with RP (70, 71, 83, 89, 94-96). Therefore, a histological analysis of the activation and infiltration of immune cells in the retina of the P23H rat would not only assess the presence of an inflammatory response, but provide information about the type of immune cells involved. Identifying the primary immune cells infiltrating the ocular tissues of the P23H rat could help determine which cytokines and chemokines are likely being expressed. This information could then be used to optimize the measurement of inflammatory changes caused by PBM. Alternatively, measuring the gene expression of NF- κ B or other inflammatory transcription factors may be used to assess the regulation of inflammation in the retina (115), as NIR light treatments have been demonstrated to modulate the expression of NF- κ B in other conditions (105).

Understanding the mechanisms of PBM is essential for achieving FDA approval, allowing it to be used for the treatment of RP patients. PBM may offer a non-invasive, easy to use treatment option with minimal side effects. Unlike gene therapy and steroid treatments, PBM does not use injections, eliminating the risk of infections or injury. The devices used to administer NIR light treatments can be small and preset, making them usable by patients at home. PBM also has the potential to be effective for a wide range of RP patients, as it is not targeted to specific mutations. Furthermore, an obstacle of other treatment methods has been the inability to halt photoreceptor cell death after degeneration has begun

(40). PBM has been shown to be able to preserve photoreceptor cells when treatment was initiated at the peak of photoreceptor cell death. This makes PBM an ideal treatment option since patients may have significant photoreceptor cell loss before RP is diagnosed (1, 8, 27, 28). The insights obtained from this research advance our knowledge about the mechanisms behind RP and PBM, bringing an effective treatment one step closer to development for RP patients.

REFERENCES

1. Hartong D. T., E. L. Berson, and T. P. Dryja. 2006. "Retinitis Pigmentosa." *Lancet* 368: 1795-1809.
2. Ammann F., D. Klein, and A. Franceschetti. 1965. "Genetic and epidemiological investigation of pigmentary degeneration of the retina and allied disorders in Switzerland." *J Neurol Sci* 2: 183-196.
3. Boughman J. A., P. M. Conneally, and W. E. Nance. 1980. "Population genetic studies of retinitis pigmentosa." *Am J Hum Genet* 32: 223-235.
4. Bunker C. H., E. L. Berson, W. C. Bromley, R. P. Hayer, and T. H. Roderick. 1984. "Prevalence of retinitis pigmentosa in Maine." *Am J Ophthalmol* 97 (3): 357-365.
5. Jay, M. 1982. "On the hereditiy of retinitis pigmentosa." *Br J Ophthalmol* 66: 405-416.
6. Dryja T. P., T. L. McGee, B. L. Hahn, G. S. Cowley, J. E. Olsson, E. Reichel, M. A. Sandberg, and E. L. Berson. 1990. "Mutations within the rhodospin gene in patients with autosomal dominate retinitis pigmentosa." *N Engl J Med* 323 (19): 1302-1307.
7. Kajiwarra K., E. L. Berson, and T. P. Dryja. 1994. "Digenic retinitis pigmentosa due to mutations at the unlinked peripherin/PDS and ROM1 loci." *Science* 264: 1604-1608.
8. Hamel C. 2006. "Retinitis Pigmentosa." *Orphanet J Rare Dis* 1 (40). doi:10.1186/1750-1172-1-40.
9. Wright A. F., C. F. Chakarova, M. M. Abd El-Aziz, and S. S. Bhattacgarta. 2010. "Photoreceptor degeneration: genetic and mechanistic dissection of a complex trait." *Nature* 11: 273-282.
10. Boughman J. A., M. Vernon, and K. A. Shaver. 1983. "Usher syndrome: definition and estimate of prevalence from two high-risk populations." *J Chronic Dis* 36: 595-603.
11. Berson E. L. 1993. "Retinitis Pigmentosa: The Friedenwald Lecture." *Invest Ophthalmol Vis Sci* 34 (5): 1659-1976.
12. Chen Y., B. Jastrzebska, P. Cao, J. Zhang, B. Wang, W. Sun, Y. Yuan, Z. Feng, and K. Palczewski. 2014. "Inherent Instability of the Retinitis Pigmentosa P23H Mutant Opsin." *J Biol Chem* 289 (13): 9288-9302.

13. Sohocki M. M., S. P. Daiger, S. J. Bowne, J. A. Rodriguez, H. Northrup, J. R. Heckenlively, D. G. Birch, H. Mintz-Hittner, R. S. Ruiz, R. A. Lewis, D. A. Saperstein, and L. S. Sullivan. 2001. "Prevalence of mutations causing retinitis pigmentosa and other inherited retinopathies." *Hum Mutat* 17: 42-51.
14. Briscoe A. D., C. Gaur, and S. Kumar. 2004. "The spectrum of human rhodopsin disease mutations through the lens of interspecific variation." *Gene* 332: 107-118.
15. Ferrari S., E. Di Iorio, V. Barbaro, D. Ponzin, F. S. Sorrentino, and F. Parmeggiani. 2011. "Retinitis Pigmentosa: Genes and Disease Mechanisms." *Curr Genomics* 12 (4): 238-249.
16. Sung C. H., C. M. Davenport, and J. Nathans. 1993. "Rhodopsin mutations responsible for autosomal dominant retinitis pigmentosa. Clustering of functional classes along the polypeptide chain." *J Biol Chem* 268 (35): 26645-26649.
17. Dryja T. P., T. L. McGee, E. Reichel, L. B. Hahn, G. S. Cowley, D. W. Yandell, M. A. Sandberg, and E. L. Berson. 1990. "A point mutation of the rhodopsin gene in one form of retinitis pigmentosa." *Nature* 343: 364-366.
18. Sakami S., T. Maeda, G. Bereta, K. Okano, M. Golczak, A. Sumaroka, A. J. Roman, A. V. Cideciyan, S. Jacobson, and K. Palczewski. 2011. "Probing the mechanisms of photoreceptor degeneration in a new mouse model of the common form of autosomal dominate retinitis pigmentosa due to P23H opsin mutations." *J Biol Chem* 286 (12): 10551-67.
19. Saliba R. S., P. M. Munro, P. J. Luthert, and M. E. Cheetham. 2002. "The cellular fate of mutant rhodopsin: quality control, degradation and aggresome formation." *J Cell Sci* 115: 2907-2918.
20. Wang T., and C. Montell. 2007. "Phototransduction and retinal degeneration in *Drosophila*." *Pflugers Arch* 454 (5): 821-47.
21. Hetz C., and H. Glimcher. 2009. "Fine-tuning of the unfolded protein response: assembling the IRE1alpha interactome." *Mol Cell* 35 (5): 551-61.
22. Lin J. H., D. Yasumura, H. R. Cohen, C. Zhang, B. Panning, K. M. Shokat, M. M. Lavail, and P. Walter. 2007. "IRE1 signaling affects cell fate during the unfolded protein response." *Science* 318: 944-949.

23. Berson E. L., M. A. Sandberg, B. Rosner, D. G. Birch, and A. H. Hanson. 1984. "Natural Course of Retinitis Pigmentosa Over a Three-Year Interval." *Amer J Ophthal* 99 (3): 240-251.
24. Farber D. B., J. R. Heckenlively, R. S. Sparkes, and J. B. Bateman. 1991. "Molecular genetics of retinitis pigmentosa." *West J Med* 155: 388-399.
25. Li Z. Y., D. E. Possin, and A. H. Milam. 1995. "Histopathology of bone spicule pigmentation in retinitis pigmentosa." *Ophthal* 102: 805-816.
26. Heckenlively, J R. 1982. "The frequency of posterior subcapsular cataract in the hereditary retinal degenerations." *Amer J Ophthal* 93: 733-738.
27. Szlyk J. P., W. Seiple, G. A. Fishman, K. R. Alexander, S. Grover, and C. L. Mahler. 2001. "Perceived and actual performance of daily tasks: relationship to visual function tests in individuals with retinitis pigmentosa." *Ophthal* 108: 65-75.
28. Geller A. M., and P. A. Sieving. 1993. "Assessment of foveal cone photoreceptors in Stargardt's macular dystrophy using a small dot detection task." *Vision Res* 33: 1509-1524.
29. Karpe, G. 1945. "Basis of clinical electroretinography." *Acta Ophthalmol Suppl* 24: 84.
30. Berson E. L., P. Gouras, and M. Hoff. 1969. "Temporal aspects of the electroretinogram." *Arch Ophthalmol* 81: 207-214.
31. Berson, E L. 1987. "Electroretinographic findings in retinitis pigmentosa." *Jpn J Ophthalmol* 31: 327-348.
32. Grant C. A., and E. L Berson. 2001. "Treatable forms of retinitis pigmentosa associated with systemic neurological disorders." *Int Ophthalmol Clin* 41: 103-110.
33. Gouras P., R. E. Carr, and R. D. Gunkel. 1971. "Retinitis pigmentosa in abetalipoproteinemia: Effects of vitamin A." *Invest Ophthalmol Vis Sci* 10: 784-793.
34. Bishara S., S. Merin, M. Cooper, E. Azizi, G. Delpre, and R. J. Deckelbaum. 1982. "Combined vitamin A and E therapy prevents retinal electrophysiological deterioration in abetalipoproteinemia." *Br J Ophthalmol* 66: 767-770.

35. Refsum, S. 1981. "Heredopathia atactica polyneuritiformis, phytanic acid storage disease, Refsum's disease: A biochemically well-defined disease with a specific dietary treatment." *Arch Neurol* 38: 605-606.
36. Hungerbuhler J. P., C. Meier, L. Rousselle, P. Quadri, and J. Bogousslavsky. 1985. "Refsum's disease: management by diet and plasmapheresis." *Eur Neurol* 24: 153-159.
37. Yokota T., T. Shiojiri, T. Gotoda, M. Arita, T. Ohga, T. Kanda, J. Suzuki, et al. 1997. "Friedreich-like ataxia with retinitis pigmentosa caused by the His101Gln mutation of the alpha-tocopherol transfer protein gene." *Ann Neurol* 41 (6): 826-832.
38. Acland G. M., G. D. Aguirre, J. Ray, Q. Zhang, T. S. Aleman, A. V. Cideciyan, S. E. Pearce-Kelling, et al. 2001. "Gene therapy restores vision in a canine model of childhood blindness." *Nat Genet* 28: 92-95.
39. Acland G. M., A. G. Aguirre, J. Bennett, T. S. Aleman, A. V. Cideciyan, J. Bennicelli, N. S. Dejneka, et al. 2005. "Long-Term Restoration of Rod and Cone Vision by Single Dose rAAV-Mediated Gene Transfer to the retina in a Canine Model of Childhood Blindness." *Mol Ther* 12 (6): 1072-1082.
40. Cideciyan A. V., S. G. Jacobson, W. A. Beltran, A. Sumaroka, M. Swider, S. Iwabe, A. J. Roman, et al. 2013. "Human retinal gene therapy for Leber congenital amaurosis shows advancing retinal degeneration despite enduring visual improvement." *PNAS* 110 (12): 517-525.
41. Jiang L., H. Zhang, A. M. Dizhoor, S. E. Boye, W. W. Hauswirth, J. M. Fredrick, and W. Baehr. 2011. "Long-term RNA interference gene therapy in a dominant retinitis pigmentosa mouse model." *PNAS* 108 (45): 18476-18481.
42. Berson E. L., B. Rosner, M. A. Sandberg, K. C. Hayes, B. W. Nicholson, C. Weigel-DiFranco, and W. Willett. 1993. "A randomized trial of vitamin A and vitamin E supplementation for retinitis pigmentosa." *Arch Ophthalmol* 111 (6): 761-72.
43. Feskanich D., V. Singh, W. C. Willett, and G. A. Colditz. 2002. "Vitamin A intake and hip fractures among postmenopausal women." *JAMA* 287: 47-54.
44. Michaelsson K., H. Lithell, B. Vessby, and H. Melhus. 2003. "Serum retinol levels and the risk of fracture." *N Engl J Med* 348: 287-94.

45. Lammer E. J., D. T. Chen, R. M. Hoar, N. D. Agnish, P. J. Benke, J. T. Braun, C. J. Curry, et al. 1985. "Retinoic Acid Embryopathy." *N Engl J Med* 313: 837-41.
46. Hoffman D. R., K. G. Locke, D. H. Wheaton, G. E. Fish, R. Spencer, and D. G. Birch. 2004. "A randomized, placebo-controlled clinical trial of docosahexaenoic acid supplementation for X-linked retinitis pigmentosa." *Am J Ophthalmol* 137: 704-718.
47. Berson E. L., B. Rosner, M. A. Sandberg, C. Weigel-DiFranco, A. Moser, R. J. Brockhurst, K. C. Hayes, et al. 2004. "Clinical trial of docosahexaenoic acid in patients with retinitis pigmentosa receiving vitamin A treatment." *Arch Ophthalmol* 122 (9): 1297-305.
48. Berson E. L., B. Rosner, M. A. Sandberg, C. Weigel-DiFranco, A. Moser, R. J. Brockhurst, K. C. Hayes, et al. 2004. "Further evaluation of docosahexaenoic acid in patients with retinitis pigmentosa receiving vitamin A treatment: subgroup analyses." *Arch Ophthalmol* 122 (9): 1306-14.
49. Cideciyan A. V., S. G. Jacobson, T. S. Aleman, D. Gu, S. E. Pearce-Kelling, A. Sumaroka, G. M. Acland, and G. D. Aguirre. 2005. "In vivo dynamics of retinal injury and repair in the rhodopsin mutant dog model of human retinitis pigmentosa." *Proc Natl Acad Sci USA* 102 (14): 5233-8.
50. Naash M. L., N. S. Peachey, Z. Y. Li, C. C. Gryczan, Y. Goto, J. Blanks, A. H. Milam, and H. Ripps. 1996. "Light-induced acceleration of photoreceptor degeneration in transgenic mice expressing mutant rhodopsin." *Invest Ophthalmol Vis Sci* 37 (5): 775-82.
51. Berson E. L. 1980. "Light deprivation and retinitis pigmentosa." *Vision Res* 20: 1179-84.
52. Miyake Y., S. Sugita, M. Horiguchi, and K. Yagasaki. 1990. "Light deprivations and retinitis pigmentosa." *Am J Ophthalmol* 110: 305-306.
53. Maclaren R. E., R. A. Pearson, A. MacNeil, R. H. Douglas, T. E. Salt, M. Akimoto, A. Swaroop, J. C. Sowden, and R. R. Ali. 2006. "Retinal repair by transplantation of photoreceptor precursors." *Nature* 444: 203-207.
54. Caspi A., J. D. Dorn, K. H. McClure, M. S. Humayun, R. J. Greenburg, and M. J. McMahon. 2009. "Feasibility study of a retinal prosthesis: spatial vision with a 16-electrode implant." *Arch Ophthalmol* 127 (4): 398-401.
55. Yanai D., J. D. Weiland, M. Mahadevappa, R. J. Greenburg, I. Fine, and M. S. Humayun. 2007. "Visual performance using a retinal prosthesis in

- three subjects with retinitis pigmentosa." *Am J Ophthalmol* 143 (5): 820-827.
56. Morohoshi K., A. M. Goodwin, M. Ohbayashi, and S. J. Ono. 2009. "Autoimmunity in retinal degeneration: Autoimmune retinopathy and age-related macular degeneration." *J Autoimmun* 33: 247-254.
 57. Niederkorn J. Y. 2007. "The induction of anterior chamber-associated immune deviation." *Chem Immunol Allergy* 92: 27-35.
 58. Cunha-Vas J. G. 2004. "The blood-retinal barrier system: basic concepts and clinical evaluation." *Exp Eye Res* 78: 751-721.
 59. Bok D. 1993. "The retinal pigment epithelium: a versatile partner in vision." *J Cell Sci Suppl.* 17: 189-95.
 60. Detrick B. and J. J. Hooks. 2010. "Immune regulation in the retina." *Immunol Res* 47: 153-161.
 61. Martínez-Fernández de la Cámara C., M. D. Sequedo, U. Gómez-Pinedo, T. Jaijo, E. Aller, P. García-Tárraga, J. M. García-Verdugo, J. M. Millán, and R. Rodrigo. 2013. "Phosphodiesterase inhibition induces retinal degeneration, oxidative stress and inflammation in cone-enriched cultures of porcine retina." *Exp Eye Res* 111: 122-133.
 62. Detrick B., M. Rodrigues, C. C. Chan, M. O. Tso, and J. J. Hooks. 1986. "Expression of HLA-DR antigen on retinal pigment epithelial cells in retinitis pigmentosa." *Am J Ophthalmol* 101: 584-90.
 63. Percopo C. M., J. J. Hooks, T. Shinohara, R. Caspi, and B. Detrick. 1990. "Cytokine-mediated activation of a neuronal retinal resident cell provokes antigen presentation." *J Immunol* 145:4101-4107.
 64. Hamel C. P., B. Detrick, and J. J. Hooks. 1990 "Evaluation of Ia expression in rat ocular tissues following inoculation with interferon-gamma." *Exp Eye Res* 50:173-82.
 65. Nagineni C. N., B. Detrick, and J. J. Hooks. 2000. "Toxoplasma gondii infection induces gene expression and secretion of interleukin 1 (IL-1), IL-6, granulocyte-macrophage colony-stimulating factor, and intercellular adhesion molecule 1 by human retinal pigment epithelial cells." *Infect Immun* 68:407-410.
 66. Nagineni C. N., W. Samuel, S. Nagineni, K. Pardhasaradhi, B. Wiggert, B. Detrick, et al. 2003. "Transforming growth factor-beta induces expression of vascular endothelial growth factor in human retinal pigment epithelial

- cells: involvement of mitogen-activated protein kinases." *J Cell Physiol* 197:453–462.
67. Nagineni C. N., V. Kutty, B. Detrick, and J. J. Hooks. 2005. "Expression of PDGF and their receptors in human retinal pigment epithelial cells and fibroblasts: regulation by TGF-beta." *J Cell Physiol* 203:35–43.
 68. Hooks J. J., C. N. Nagineni, L. C. Hooper, K. Hayashi, and B. Detrick. 2008. "IFN-beta provides immuno-protection in the retina by inhibiting ICAM-1 and CXCL9 in retinal pigment epithelial cells." *J Immunol* 180:3789–3796.
 69. Kreutzberg G. W. 1996. "Microglia: a sensor for pathological events in the CNS." *Trends Neurosci* 19: 312-318.
 70. Glybina I. V., A. Kennedy, P. Ashton. G. W. Abrams, and R. Iezzi. 2010. "Intravitreal Delivery of the Corticosteroid Fluocinolone Acetonide Attenuates Retinal Degeneration in S334ter-4 Rats." *Invest Ophthalmol Vis Sci* 51(8): 4243-4252.
 71. Kohno H., T. Maeda, L. Perusek, E. Pearlman, and A. Maeda. 2014. "CCL3 Production by Microglial Cells Modulates Disease Severity in Murine Models of Retinal Degeneration." *J Immunol* 192: 3816-3827.
 72. Langmann T. 2007. "Microglia activation in retinal degeneration." *J Leukoc Biol* 81: 1345–1351.
 73. Pawate S., Q. Shen, F. Fan, and B. R. Bhat. 2004. "Redox regulation of glial inflammatory response to lipopolysaccharide and interferon-gamma." *J Neurosci Res* 77: 540-551.
 74. Kaneko H., K. M. Nishiguchi, M. Nakamura, et al. 2008. "Characteristics of bone marrow-derived microglia in the normal and injured retina." *Invest Ophthalmol Vis Sci* 49: 4162– 4168.
 75. Banati R. B., J. Gehrmann, P. Schubert, and G. W. Kreutzberg. 1993 "Cytotoxicity of microglia." *Glia* 7: 111-118.
 76. Boje K. M. and P. K. Arora. 1992. "Microglial-produced nitric oxide and reactive nitrogen oxides mediate neuronal cell death." *Brain Res* 587: 250-256.
 77. Kim Y. S. and T. H. Joh. 2006. "Microglia, major player in the brain inflammation: their roles in the pathogenesis of Parkinson's disease." *Exp Mol Med* 38: 333– 347.

78. Marques C. P., M. C. Cheeran, J. M. Palmquist, S. Hu, S. L. Urban, and J. R. Lokensgard. 2008. "Prolonged microglial cell activation and lymphocyte infiltration following experimental herpes encephalitis." *J. Immunol* 181: 6417–6426.
79. Getts D. R., R. L. Terry, M. T. Getts, M. McEuler, S. Rana, B. Shrestha, J. Radford, N. Van Rooijen, I. L. Campbell, and N. J. King. 2008. "Ly6c+ "inflammatory monocytes" are microglial precursors recruited in a pathogenic manner in West Nile virus encephalitis." *J. Exp. Med* 205: 2319–2337.
80. Tai Y. F., N. Pavese, A. Gerhard, et al. 2007. "Imaging microglial activation in Huntington's disease." *Brain Res Bull* 72: 148-151.
81. Turner M. R. A. Cagnin, F. E. Turkheimer, et al. 2004. "Evidence of widespread cerebral microglial activation in amyotrophic lateral sclerosis: an [11C](R)-PK11195 positron emission tomography study." *Neurobiol Dis* 15: 601-609.
82. Ng T. F. and J. W. Streilein. 2001. "Light-induced migration of retinal microglia into the subretinal space." *Invest Ophthalmol Vis Sci* 42: 3301-3310.
83. Gupta N., K. E. Brown, and A. H. Milam. 2003. "Activated microglia in human retinitis pigmentosa, late-onset retinal degeneration, and age-related macular degeneration." *Exp Eye Res* 76: 463–71.
84. Roque R. S., C. J. Imperial, and R. B. Caldwell. 1996. "Microglial cells invade the outer retina as photoreceptors degenerate in Royal College of Surgeon rats." *Invest Ophthalmol Vis Sci* 37: 196-203.
85. Pruett R. C. 1983. "Retinitis pigmentosa: clinical observations and correlations." *Trans Am Ophthalmol Soc* 81:693–735.
86. Fessel W. J. 1962. "Serumprotein disturbance in retinitis pigmentosa. And the association of retinitis pigmentosa with psychosis." *Amer J Ophthalmol* 53(4): 640–642.
87. Rahi A. H. 1973. "Autoimmunity and the retina. II. Raised serum IgM levels in retinitis pigmentosa." *Br J Ophthalmol* 57(12): 904–909.
88. Brinkman C. J. J., A. J. L. G. Pinckers, and R. M. Broekhuysen. 1980. "Immune reactivity to different retinal antigens in patients suffering from retinitis pigmentosa." *Invest Ophthalmol Vis Sci* 19(7): 743–750.

89. Newsome D.A. and R. G. Michels. 1988. "Detection of lymphocytes in the vitreous gel of patients with retinitis pigmentosa." *Am J Ophthalmol* 105: 596–602.
90. Yoshimura T., K-H Sonoda, M. Sugahara, Y. Mochizuki, H. Enaida, Y. Oshima, et al. 2009. "Comprehensive Analysis of Inflammatory Immune Mediators in Vitreoretinal Diseases." *PLoS ONE* 4(12): e8158. doi:10.1371/journal.pone.0008158
91. Roh M. I., H. S. Kim, J. H. Song, et al. 2009. "Effect of intravitreal bevacizumab injection on aqueous humor cytokine levels in clinically significant macular edema." *Ophthalmol* 116: 80–86.
92. Funatsu H., H. Yamashita, H. Noma, et al. 2005. "Aqueous humor levels of cytokines are related to vitreous levels and progression of diabetic retinopathy in diabetic patients." *Graefes Arch Clin Exp Ophthalmol* 243: 3– 8.
93. McGeer E.G., A. Klegeris, and P. L. McGeer. 2005. "Inflammation, the complement system and the diseases of aging." *Neurobiol Aging* 26: 94 – 97.
94. Zeng H. Y., X. A. Zhu, C. Zhang, L. P. Yang, L. M. Wu, and M. O. M. Tso. 2005. "Identification of sequential events and factors associated with microglial activation, migration, and cytotoxicity in retinal degeneration in rd mice," *Invest Ophthalmol Vis Sci* 46(8): 2992–2999.
95. Yoshida N., Y. Ikeda, S. Notomi, K. Ishikawa, Y. Murakami, T. Hisatomi, H. Enaida, and T. Ishibashi, 2013. "Clinical Evidence of Sustained Chronic Inflammatory Reaction in Retinitis Pigmentosa." *Ophthalmol* 120: 100-105.
96. Yoshida N., Y. Ikeda, S. Notomi, K. Ishikawa, Y. Murakami, T. Hisatomi, H. Enaida, and T. Ishibashi, 2013. "Laboratory Evidence of Sustained Chronic Inflammatory Reaction in Retinitis Pigmentosa." *Ophthalmol* 120: e5-e12.
97. Albarracin R., J. Eells, and K. Valter. 2011. "Photobiomodulation Protects the Retina from Light-Induced Photoreceptor Degeneration." *IOVS* 52:3582-92.
98. Eells J. T., M. M. Henry, P. Summerfelt, M. T. T. Wong-Riley, E. V. Buchmann, M. Kane, N. T. Whelan, and H. T. Whelan. 2003. "Therapeutic photobiomodulation for methanol-induced retinal toxicity." *PNAS* 100:3439-3444.

99. Hamblin M. and T. Demidova-Rice. 2007. "Cellular chromophores and signaling in low level light therapy." *SPIE* article id: 642802.
100. Szymanski C. R., W. Chiha, N. Morellini, N. Cummins, C. A. Bartlett, R. L. Doig, D. L. Savigni, S. C. Payne, A. R. Harvey, S. A. Dunlop, and M. Fitzgerald. 2013. "Paranode Abnormalities and Oxidative Stress in Optic Nerve Vulnerable to Secondary Degeneration: Modulation by 670 nm Light Treatment." *PloS ONE*. 8:e66448.
101. Begum R., M. B. Powner, N. Hudson, C. Hogg, and G. Jeffery. 2013. "Treatment with 670 nm Light Up Regulates Cytochrome C Oxidase Expression and Reduces Inflammation in an Age-Related Macular Degeneration Model." *PLoS ONE* 8: e57828.
102. Huang Y., A. C.-H. Chen, J. D. Carroll, and M. R. Hamblin. 2009. "Biphasic Dose Response in Low Level Light Therapy." *Dose-Response* DOI:10.2203/dose-response.09-027.Hamblin.
103. Muili K. A., S. Gopalakrishnan, J. T. Eells, and J. Lyons. 2013. "Photobiomodulation Induced by 670 nm Light Ameliorates MOG35-55 Induced EAE in Female C57BL/6 Mice: A Role for Remediation of Nitrosative Stress." *PLoS ONE* 8: e67358.
104. Muili K., S. Gopalakrishnan, S. Meyer, J. Eells, and J. Lyons. 2012. "Amelioration of Experimental Autoimmune Encephalomyelitis in C57BL/6 Mice by Photobiomodulation Induced by 670 nm Light." *PLoS ONE* 7: e30655.
105. Assis L., A. I.S. Moretti, T. B. Abrahão, V. Cury, H. P. Souza, M. R. Hamblin, and N. A. Parizotto. 2012. "Low-Level Laser Therapy (808 nm) Reduces Inflammatory Response and Oxidative Stress in Rat Tibialis Anterior Muscle After Cryolesion." *Lasers Surg Med* 44: 726–735.
106. Yamaura M., M. Yao, I. Yaroslavsky, R. Cohen, M. Smotrich and I. E. Kochevar. 2009. "Low level light effects on inflammatory cytokine production by rheumatoid arthritis synoviocytes." *Lasers Surg Med* 41: 282–290.
107. Di Marco F., S. Romeo, C. Nandasena, S. Purushothuman, C. Adams, S. Bisti, and J. Stone. 2013. "The time course of action of two neuroprotectants, dietary saffron and photobiomodulation, assessed in the rat retina." *Am J Neurodegener Dis* 2(3): 208-220.
108. Natoli R., K. Valter, M. Barbosa, J. Dahlstrom, M. Rutar, A. Kent, and J. Provis. 2013. "670nm Photobiomodulation as a Novel Protection against

- Retinopathy of Prematurity: Evidence from Oxygen Induced Retinopathy Models." *PLoS ONE* 8(8): e72135.
109. Kokkinopoulos I., A. Colman, C. Hogg, J. Heckenlively, and G. Jeffery. 2013. "Age-related retinal inflammation is reduced by 670 nm light via increased mitochondrial membrane potential." *Neurobiol Aging* 34: 602-609.
 110. Gopalakrishnan S., 2012. "Photobiomodulation in Inherited Retinal Degeneration" *Theses and Dissertations*. Paper 4.
 111. Steinberg R.H., J. G. Flannery, M. Naash, P. Oh, M. T. Matthes, D. Yasumura, C. Lau-Villacorta, J. Chen, and M. M. LaVail. 1996. "Transgenic rat models of inherited retinal degeneration caused by mutant opsin genes." *Invest Ophthalmol Vis Sci* 37: S698.
 112. LaVail M. M. 2011. "Retinal Degeneration Rat Model Resource Availability of P23H and S334ter Mutant Rhodopsin Transgenic Rats and RCS Inbred and Congenic Strains." University of California, San Francisco. Retrieved June 15, 2015 from <http://www.ucsfeye.net/mlavailRDratmodels.shtml>.
 113. Nakagawa H., N. Komorita, F. Shibata, A. Ikesue, K. Konishi, M. Fujioka, and H. Kato. 1994. "Identification of cytokine-induced neutrophil chemoattractants (CINC), rat GRO/CINC-2 alpha and CINC-2 beta, produced by granulation tissue in culture: purification, complete amino acid sequences and characterization." *Biochem J* 301: 545-550.
 114. Murakami K., F. Shibata, M. al-Mokdad, H. Nakagawa, A. Ueno, and T. Kondo. 1997. "Identification and characterization of receptor for cytokine-induced neutrophil chemoattractant-3 on rat neutrophils." *Biochem Biophys Res Commun* 232(2): 562-567.
 115. Murphy K. 2012. "Janeway's Immunobiology 8th Edition." New York, NY: *Garland Science*.
 116. Planck S. R., X. N., Huang, J. E. Robertson, and J. T. Rosenbaum. 1993. "Retinal pigment epithelial cells produce interleukin-1 beta and granulocyte-macrophage colony-stimulating factor in response to interleukin-1 alpha." *Curr Eye Res* 12(3): 205-212.
 117. Neurath M. F. and S. Finotto. 2011. "IL-6 signaling in autoimmunity, chronic inflammation and inflammation-associated cancer." *Cytokine Growth F R* 22(2): 83-89.

118. Tezel G., L. Y. Li, R. V. Patil, and M. B. Wax. 2001. "TNF-alpha and TNF-alpha receptor-1 in the retina of normal and glaucomatous eyes." *Invest Ophthalmol Vis Sci* 42(8): 1787-1794.
119. Berger S., S. I. Savitz, S. Nijhawan, M. Singh, J. David, P. S. Rosenbaum, and D. M. Rosenbaum. 2008. "Deleterious role of TNF-alpha in retinal ischemia-reperfusion injury." *Invest Ophthalmol Vis Sci* 49(8): 3605-3610.
120. Geiger K., E. Howes, M. Gallina, X. J. Huang, G. H. Travis, and N. Sarvetnick. 1994. "Transgenic mice expressing IFN-gamma in the retina develop inflammation of the eye and photoreceptor loss." *Invest Ophthalmol Vis Res* 35(6): 2667-2681.
121. Yuzbasioglu E., O. Artunay, R. Rasier, A. Sengul, and H. Bahcecioglu. 2009. "Intravitreal bevacizumab (Avastin) injection in retinitis pigmentosa." *Curr Eye Res* 34(3): 231-237.
122. Spilsbury K., K. L. Garrett, P. E. Rakoczy, et al. 2000. "Overexpression of Vascular Endothelial Growth Factor (VEGF) in the Retinal Pigment Epithelium Leads to the Development of Choroidal Neovascularization." *Am J Pathol* 157(1): 135-144.
123. Silva A. G., P. Campello-Costa, R. Linden, and A. Sholl-Franco. 2008. "Interleukin-4 blocks proliferation of retinal progenitor cells and increases rod photoreceptor differentiation through distinct signaling pathways." *J Neuroimmunol* 196(1): 82-93.
124. Lemaitre C., B. Thillaye-Goldenberg, M. Naud, and Y. de Kozak. 2001. "The Effects of Intraocular Injection of Interleukin-13 on Endotoxin-Induced Uveitis in Rats." *Invest Ophthalmol Vis Sci* 42: 2022-2030.
125. Lee Y. S., A. Amadi-obi, C. E. Egwuagu, et al. 2011. "Retinal cells suppress intraocular inflammation (uveitis) through production of interleukin-27 and interleukin-10." *Immunology* 132(4): 492-502.
126. Rizzo L. V., H. Xu, C. Chan, B. Wiggert, and R. R. Caspi. 1998. "IL-10 has a protective role in experimental autoimmune uveoretinitis." *Int Immunol* 10(6): 807-814.
127. Ji Y., W. Yu, Y. S. Eom, F. Bruce, C. M. Craft, N. M. Grzywacz, and E. Lee. 2015. "The Effect of TIMP-1 on the Cone Mosaic in the Retina of the Rat Model of Retinitis Pigmentosa." *Invest Ophthalmol Vis Sci* 56: 352-364.

128. Ahuja S., P. Ahuja, A. R. Caffé, P. Ekstrom, M. Abrahamson, and T. van Veen. 2006. "rd1 mouse retina shows imbalance in cellular distribution and levels of TIMP-1/MMP-9, TIMP-2/MMP-2 and sulfated glycosaminoglycans." *Ophthalmol Res* 38(3): 125-136.
129. Pagenstecher A. A. K. Stalder, C. L. Kincaid, S. D. Shapiro, and I. L. Campbell. 1998. "Defferential expression of matrix metalloproteinase and tissue inhibitor of matrix metalloproteinase genese in the mouse central nervous system in normal and inflammatory states." *Am J Pathol* 152: 729-741.
130. Gomez D. E., D. F. Alonso, H. Yoshiji, and U. P. Thorgeirsson. 1997. "Tissue inhibitors of metalloproteinases: structure, regulation and biological functions." *Eur J Cell Biol* 74: 111-122.
131. Gottschell P. E. and S. Deb. 1996. "Regulation of matrix metalloproteinase expressions in astrocytes, microglia and neurons." *Neuroimmunmodulation* 3(2) 69-75.
132. Wong-Riley M., H. L. Liang, J. T. Eells, B. Chance, M. M. Henry, E. Buchmann, M. Kane, and H. T. Whelan. 2005. "Photobiomodulation Directly Benefits Primay Neurons Functionally Inactivated by Toxins." *J Biol Chem* 280(6): 4761-4771.
133. Hashmi J. T., Y. Huang, B. Z. Osmani, S. K. Sharma, M. A. Naeser, and M. R. Hamblin. 2011. "Role of Low-Level Laser Therapy in Neurorehabilitation." *PM R* 2(12 Suppl 2): S292-S305.
134. Giacci M. K., L. Wheeler, S. Lovett, E. Dishington, B. Majda, et al. 2014. "Differential Effects of 670 and 830nm Red near Infrared Irradiation Therapy: A Comparative Study of Optic Nerve Injury, Retinal Degeneration, Traumatic Brain and Spinal Cord Injury." *PLoS ONE* 9(8): e104565.
135. Yu D., S. Cringle, K. Valter, N. Walsh, D. Lee, and J. Stone. 2004. "Photoreceptor Death, Trophic Factor Expression, Retinal Oxygen Status, and Photoreceptor Function in the P23H Rat." *Invest Ophthalmol Vis Sci* 45(6): 2013-2019.
136. Kapsoritakis A. N., A. I. Kapsoritaki, I. P. Davidi, V. D. Lotis, A. C. Manolakis, P. I. Mylonis, A. T. Theodoridou, A. E. Germanis, and S. P. Potamianos. 2008. "Imbalance of tissue inhibitors of metalloproteinases (TIMP) – 1 and – 4 serum levels, in patients with inflammatory bowel disease." *BMC Gastroenterol* 8(55): doi:10.1186/1471-230X-8-55.

137. Zhu C. L., W. T. Li, Y. Li, and R. T. Gao. 2012. "Serum levels of tissue inhibitor of metalloproteinase-1 are correlated with liver fibrosis in patients with chronic hepatitis B." *J Digest Dis* 13: 558–563.
138. Wang P., P. Wu, M. I. Siegel, R. W. Egan, and M. M. Billah. 1995. "Interleukin (IL)-10 inhibits Nuclear Factor κ B (NF κ B) Activation in Human Monocytes." *J Biol Chem* 270(16): 9558-9563.
139. Mahanta A., S. K. Kar, S. Kakati, and S. Baruah. 2015. "Heightened inflammation in severe malaria is associated with decreased IL-10 expression levels and neutrophils." *Innate Immun* 21(5): 564-552.
140. Puiq P., F. Miro, A. Salas-Perdomo, E. Bonfill-Teixidor, M. Ferrer-Ferrer, L. Marquez-Kisinousky, and A. M. Planas. 2013. "IL-10 deficiency exacerbates the brain inflammatory response to permanent ishcemis without preventing resolution of the lesion." *J Cereb Blood Flow Metab* 33(12): 1955-1966.
141. Saadane A., J. Soltys, and M. Berger. 2005. "Role of IL-10 deficiency in excessive nuclear factor-kappaB activation and lung inflammation in cystic fibrosis transmembrane conductance regulator knockout mice." *J Allergy Clin Immunol* 115(2): 405-411.
142. Guex-Crosier Y., A. J. Wittwer, and F. G. Roberge. 1996. "Intraocular production of a cytokine (CINC) responsible for neutrophil infiltration in endotoxin induced uveitis." *Br J Ophthalmol* 80(7): 649-653.